

**Papillary Thyroid Carcinoma:  
Follicular Variant Encapsulated Type**

**Replaced by:**

**Non-Invasive Follicular Thyroid  
Neoplasm with Papillary-like  
Nuclei (NIFTP)**

**Lester D. R. Thompson**

**[www.lester-thompson.com](http://www.lester-thompson.com)**

# Overall Objectives

- **Provide a review of the key histologic features to render the new diagnosis**
- **Specifically list exclusion criteria**
- **Give examples of the features from sample cases**
- **Provide the scoring system**
- **Allow for questions/discussion before the cases are scored**

# Thyroid Papillary Carcinoma: Classic Morphologic Features

## Architectural

- ◆ Vascular or capsular invasion
- ◆ Variable growth patterns
- ◆ Elongated and/or twisted follicles
- ◆ Calcospherites (psammoma bodies)
- ◆ Intratumoral fibrosis
- ◆ Tincture of colloid (bright and rich) & scalloping
- ◆ Crystals or giant cells in the colloid

## Cytomorphologic/Nuclear

- ◆ Enlarged cells (compared to normal thyroid)
- ◆ High nuclear to cytoplasmic ratio
- ◆ Nuclear overlapping, crowding
- ◆ Irregular placement around follicle
- ◆ Nuclear grooving/folding
- ◆ Intranuclear cytoplasmic inclusions
- ◆ Pale chromatin with chromatin margination/condensation and clearing
  - ✓ Orphan Annie Nuclei

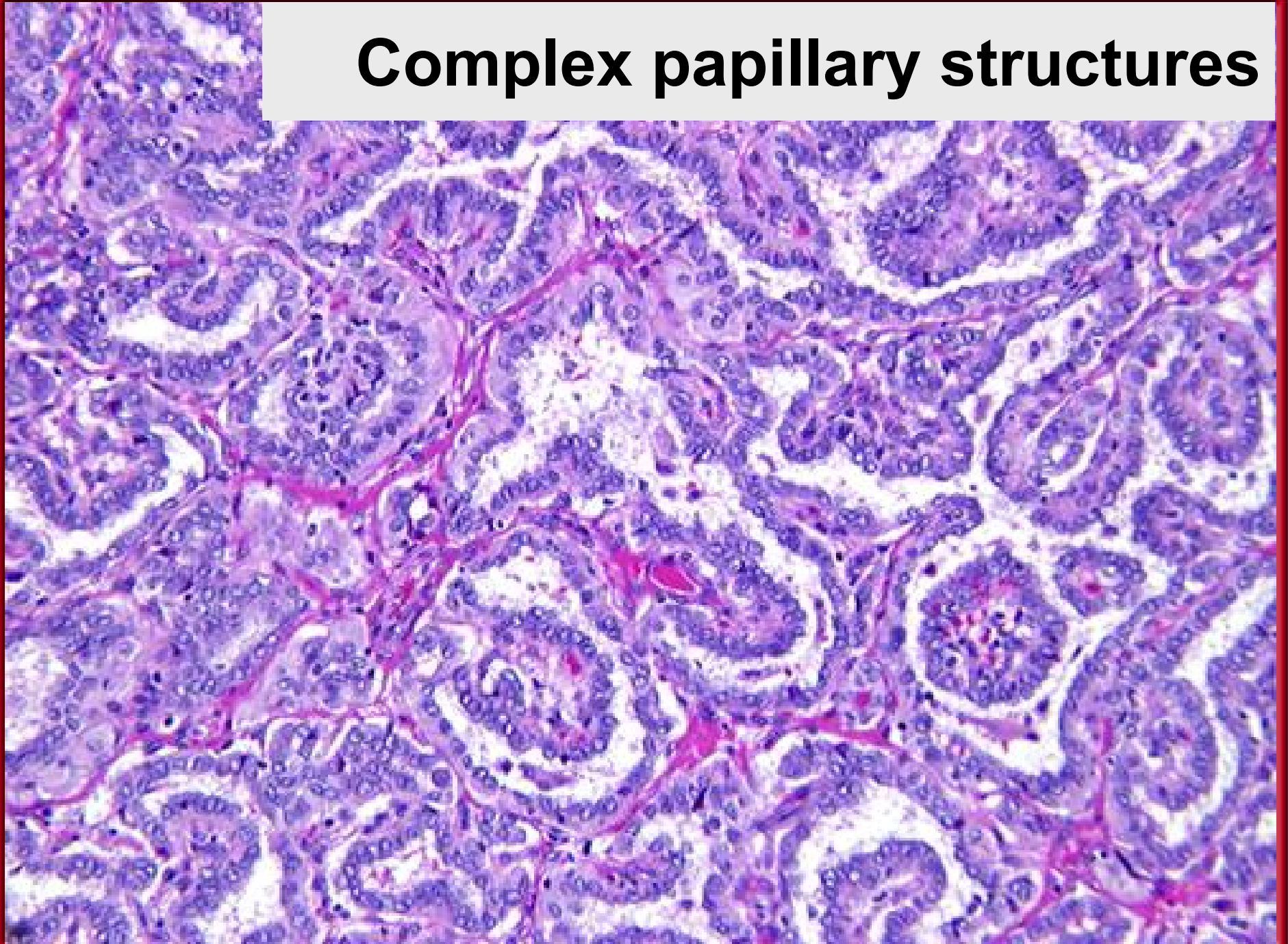
# Thyroid Papillary Carcinoma: Classic Morphologic Features

## Architectural

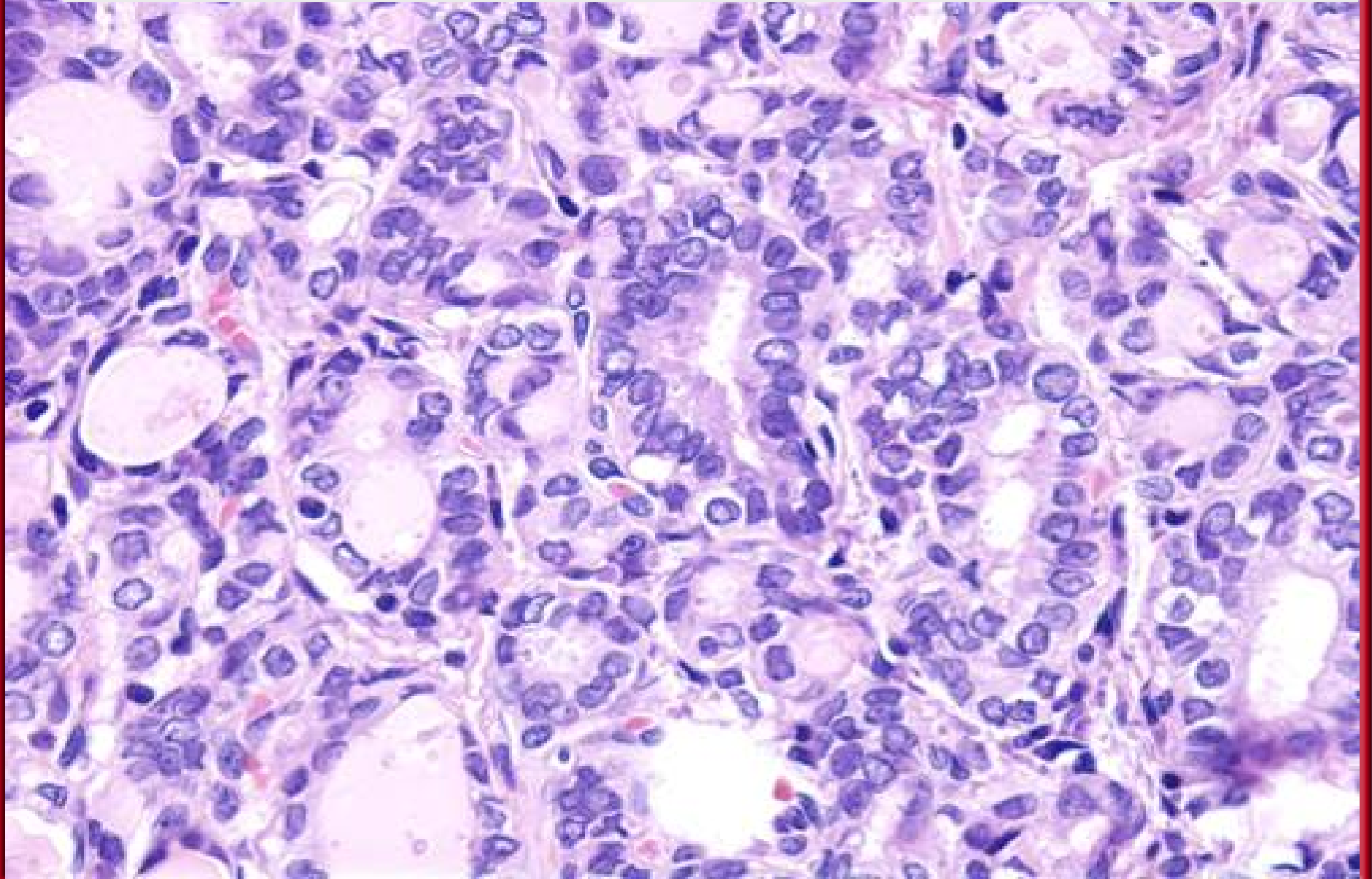
- ◆ Vascular or capsular invasion
- ◆ Variable growth patterns
- ◆ Elongated and/or twisted follicles
- ◆ Calcospherites (psammoma bodies)
- ◆ Intratumoral fibrosis
- ◆ Tincture of colloid (bright and rich) & scalloping
- ◆ Crystals or giant cells in the colloid



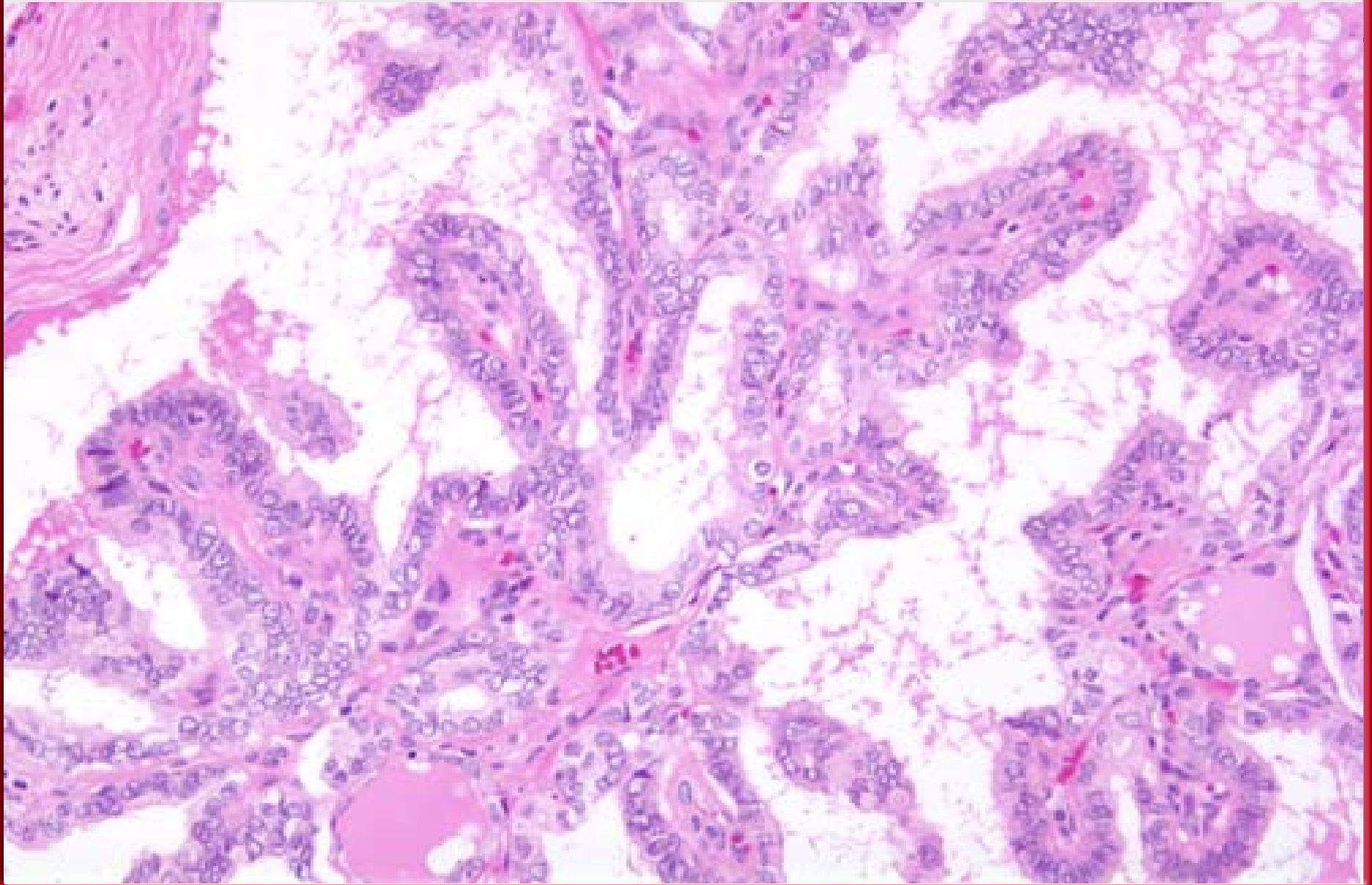
# Complex papillary structures



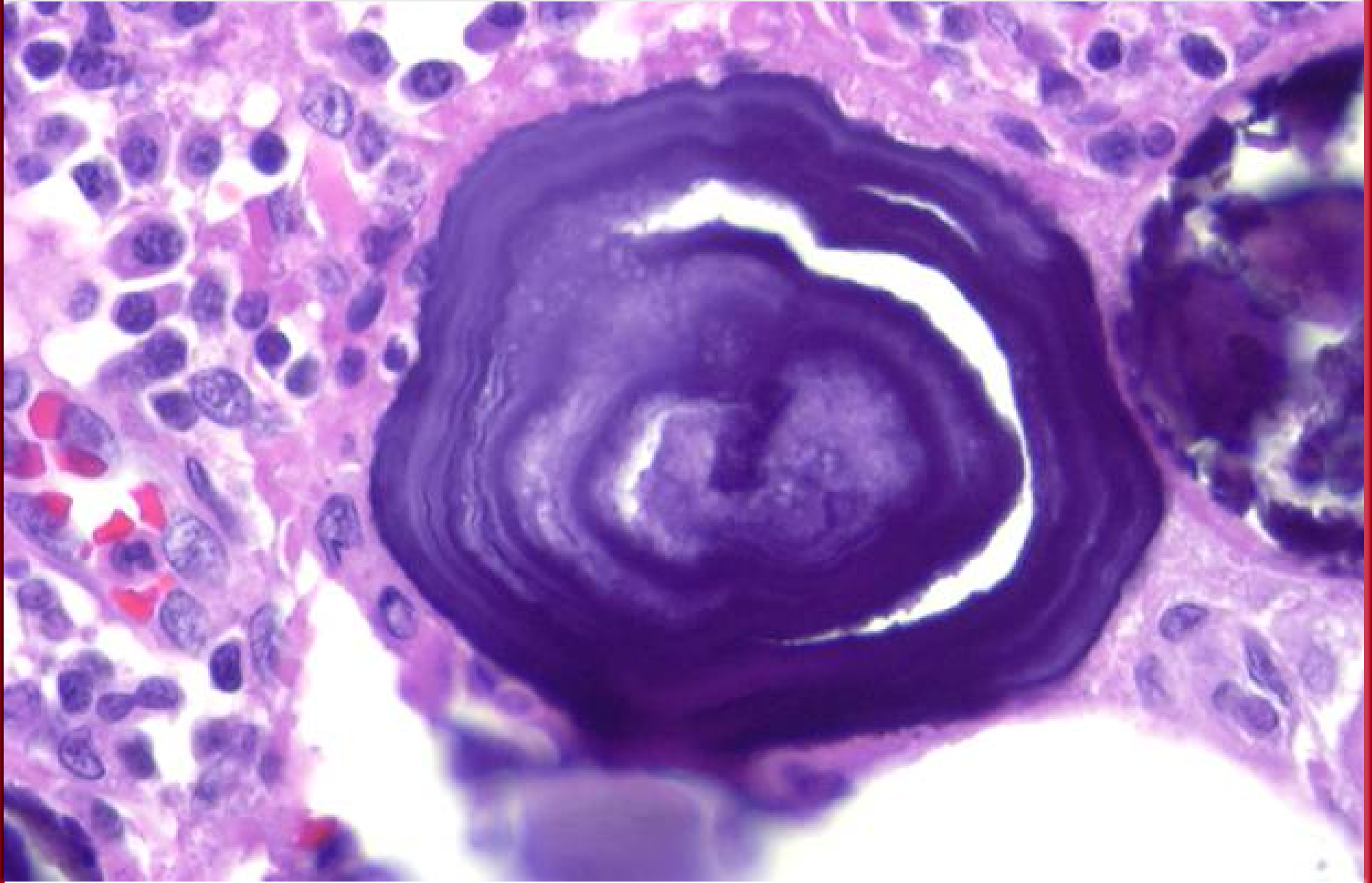
# Overlapping nuclei in twisted follicles



# Colloid and papillary structures

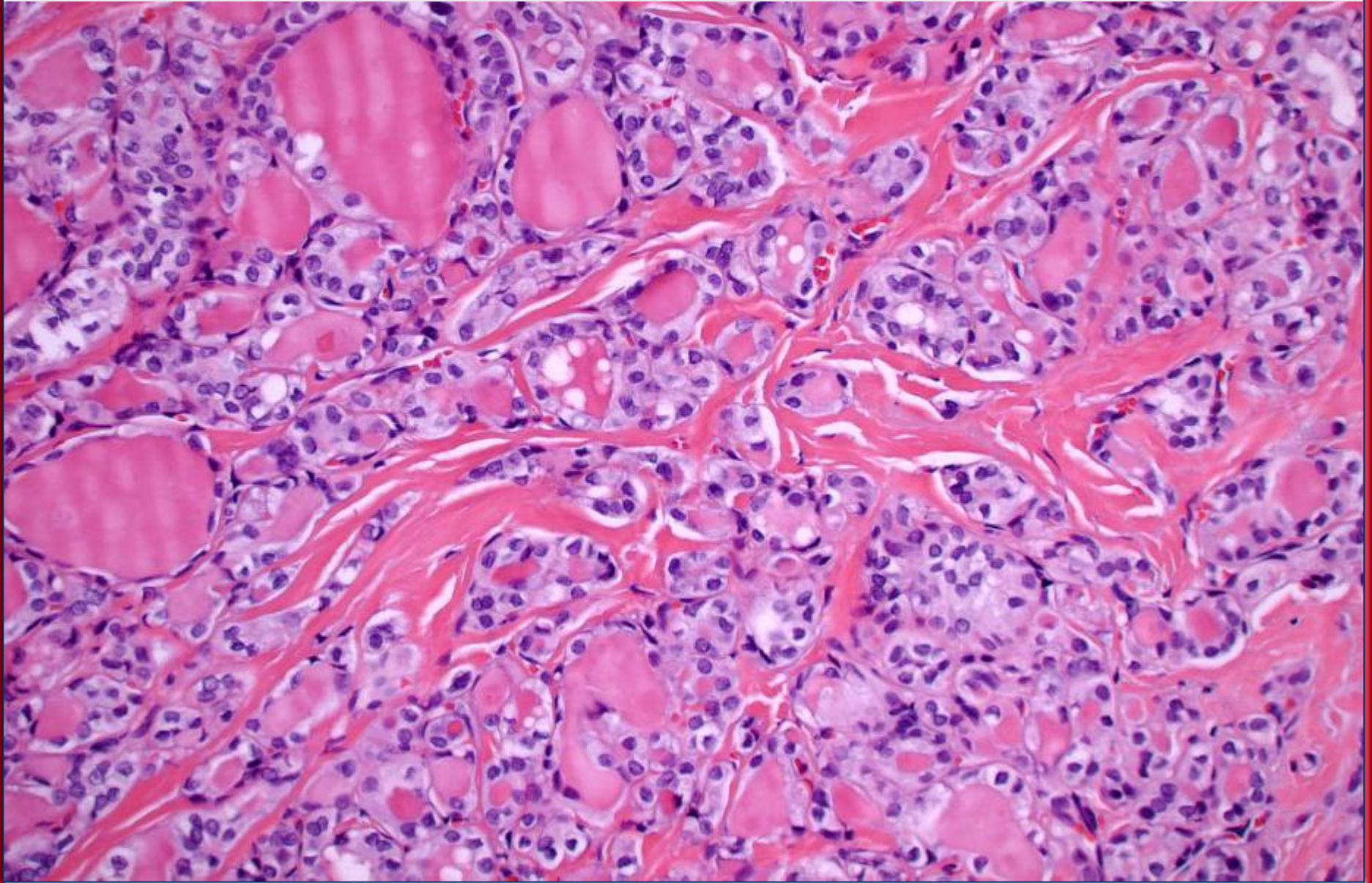


# Psammoma body

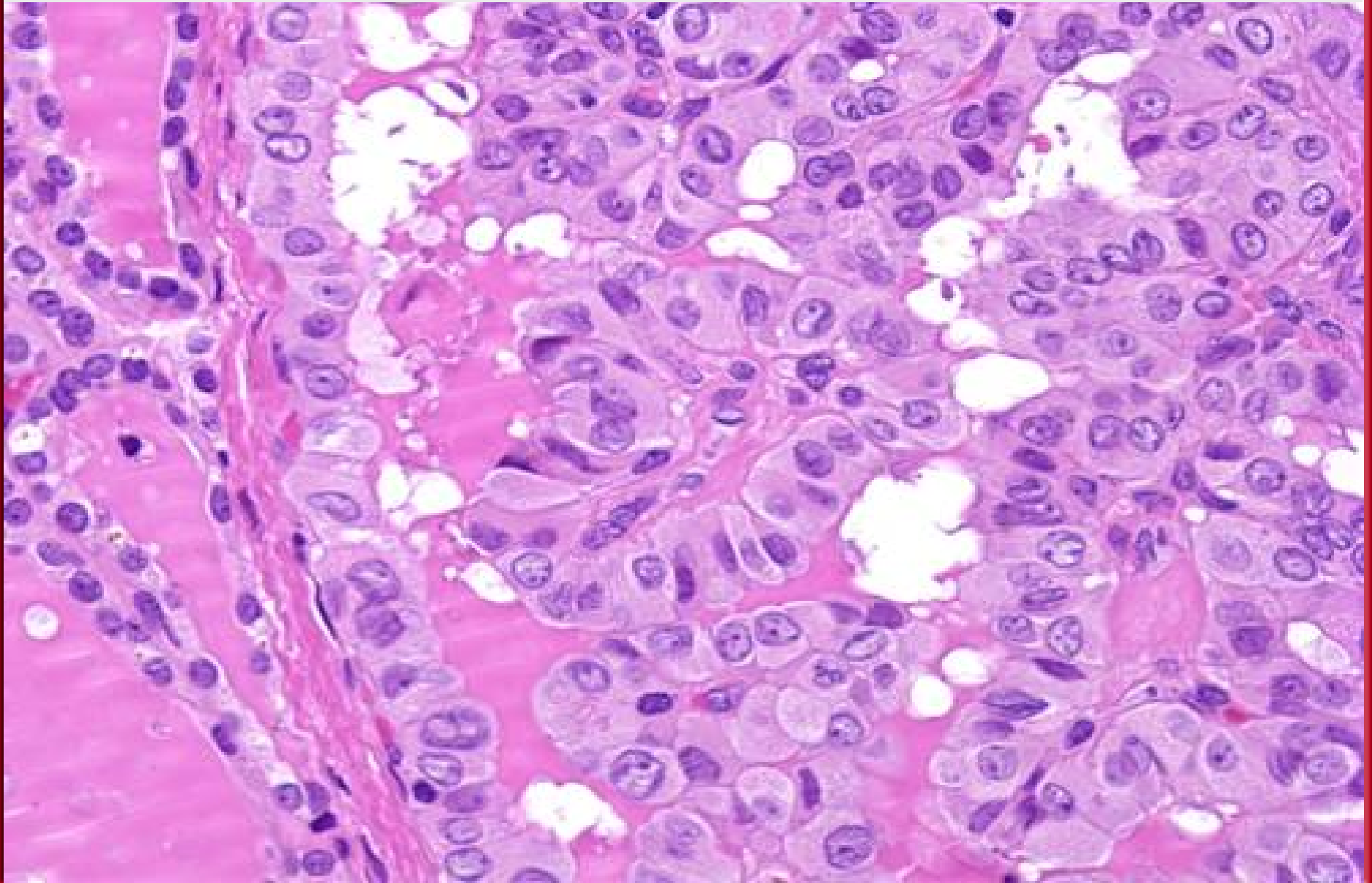




# Intratumor fibrosis and Bright Colloid

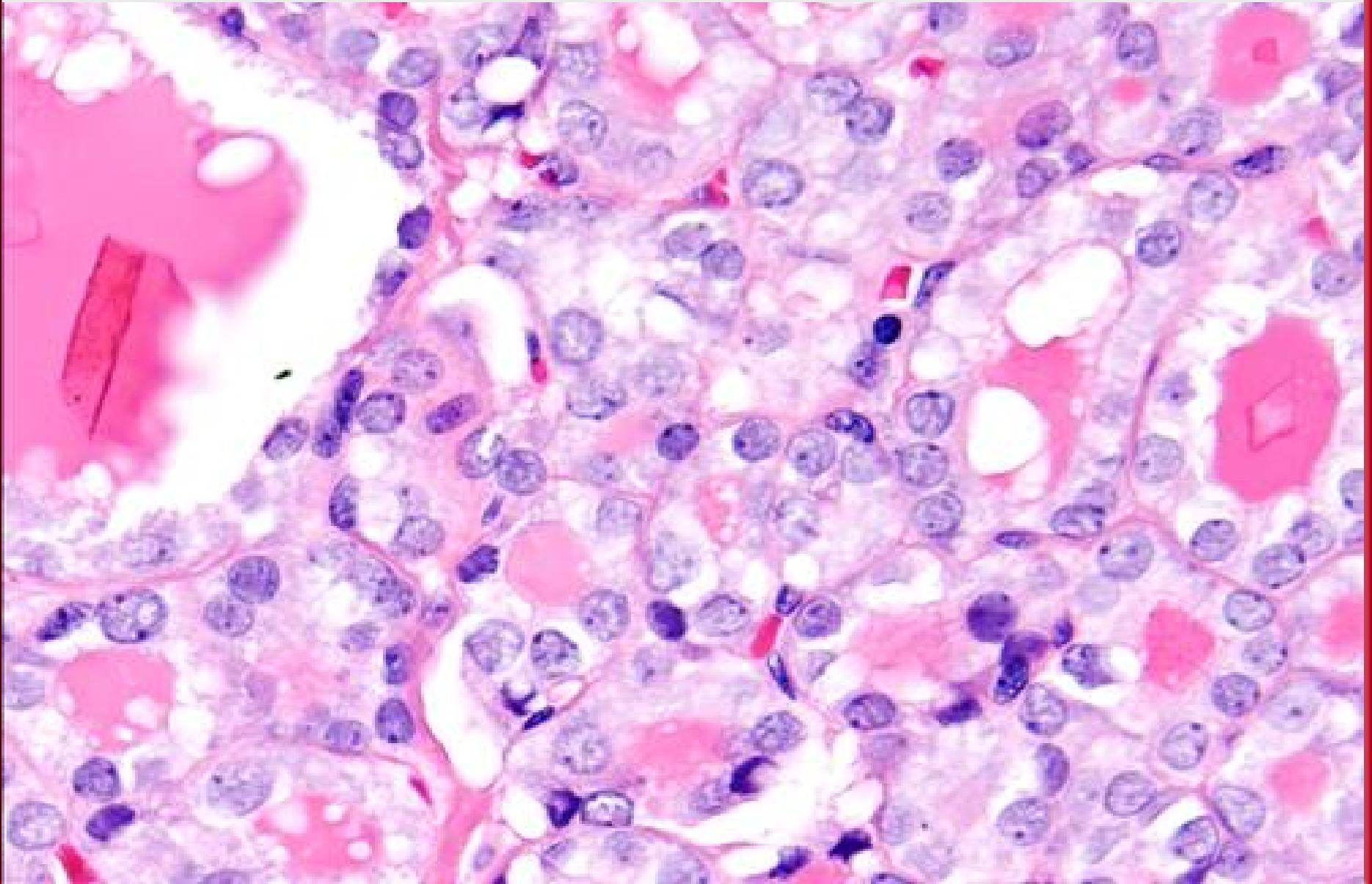


**Cellular enlargement with  $\uparrow\uparrow$  N:C ratio**

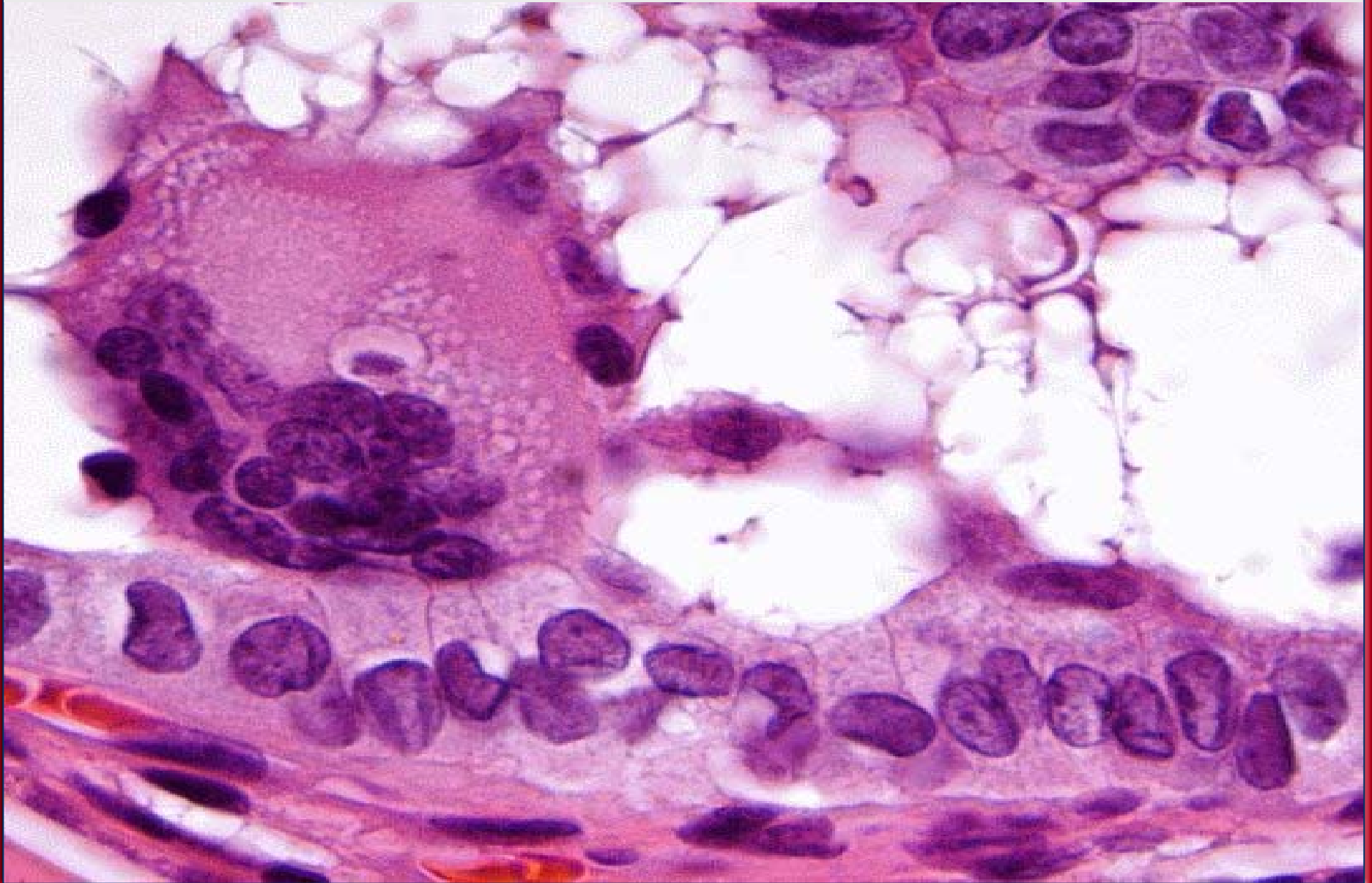




# Even/fine Chromatin; Colloid Crystalloids



# Delicate Chromatin and Giant Cells

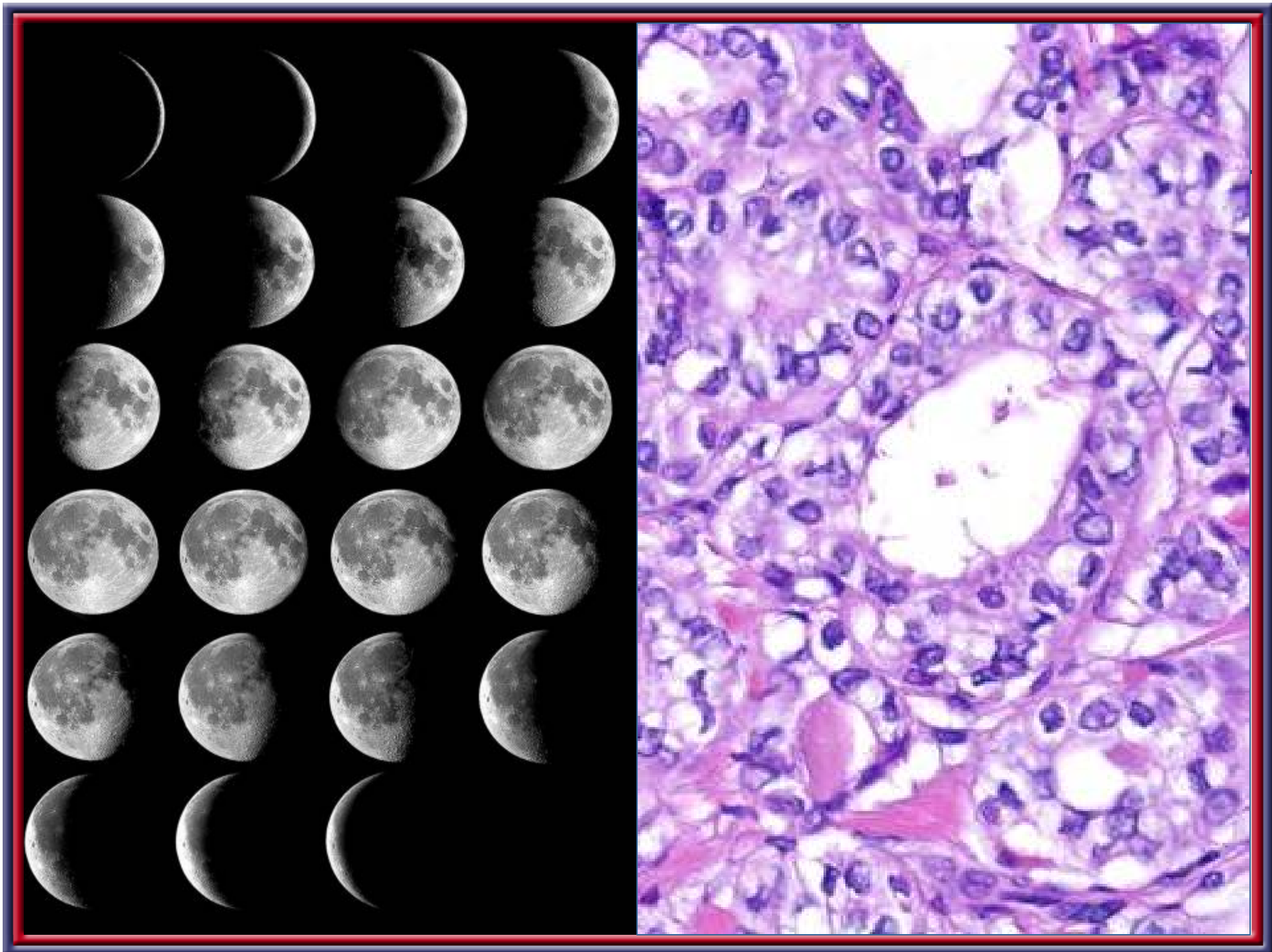




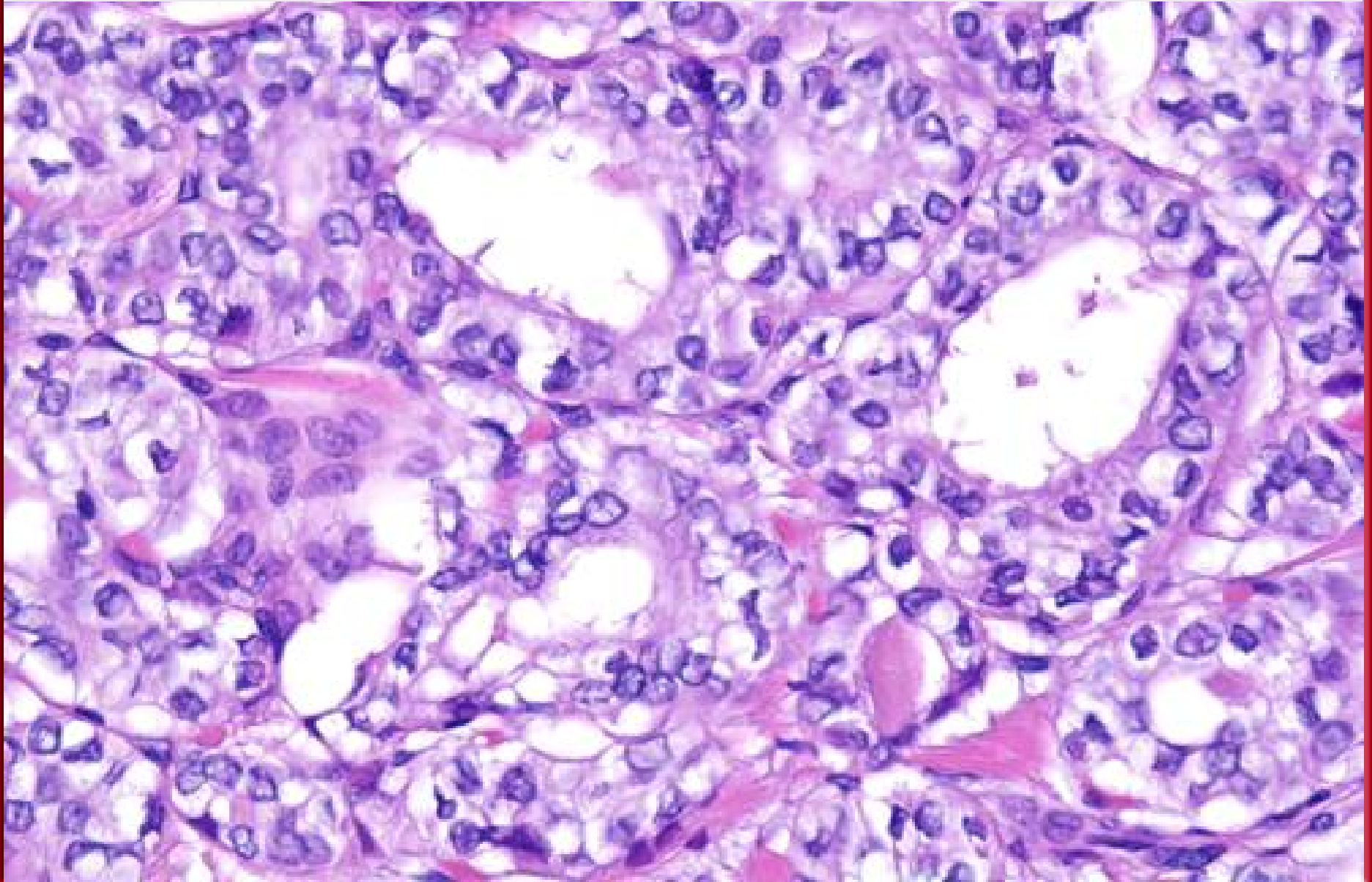
# Thyroid Papillary Carcinoma: Classic Morphologic Features

## Cytomorphologic/Nuclear

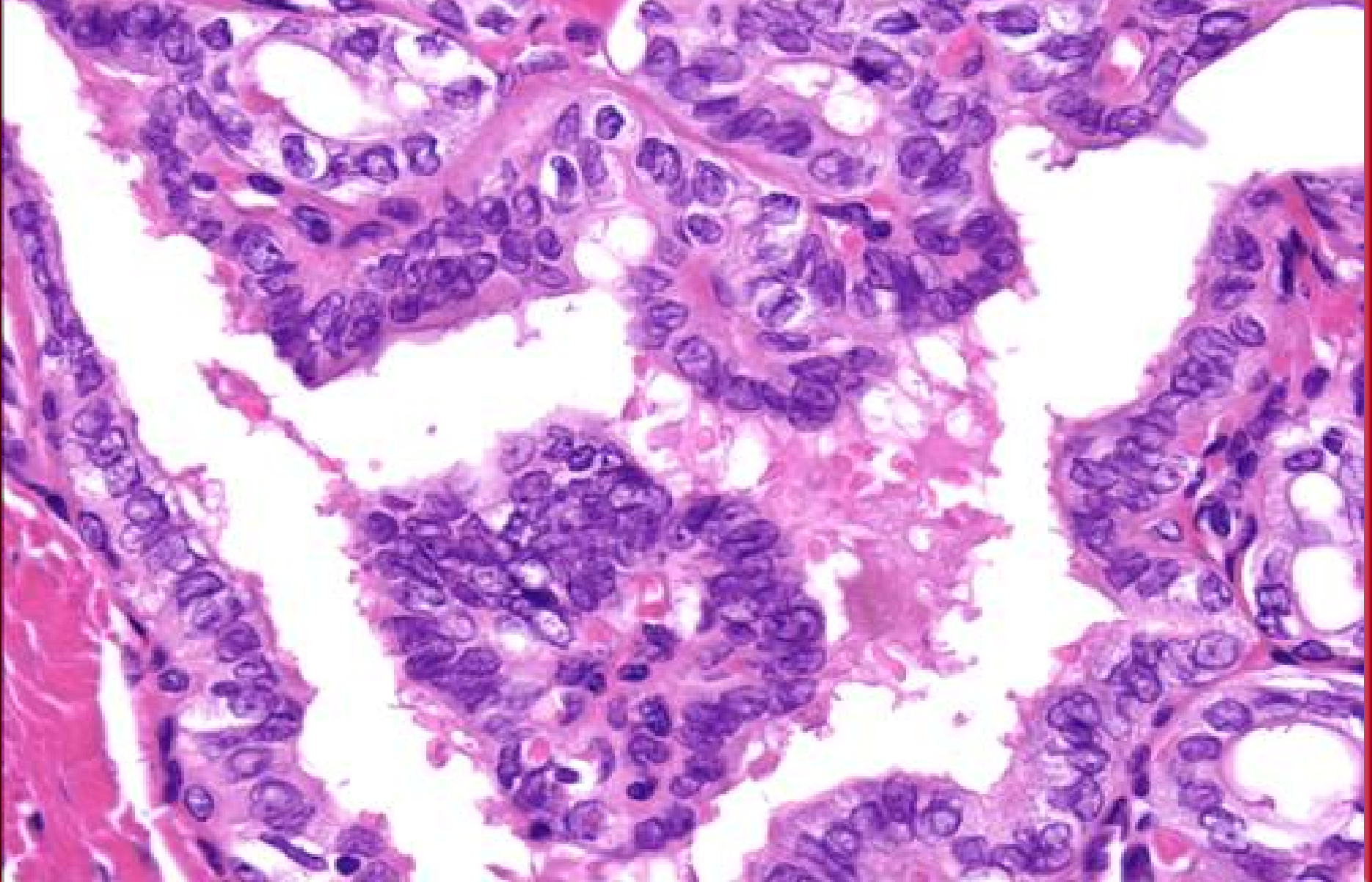
- ◆ Enlarged cells (compared to normal thyroid)
- ◆ High nuclear to cytoplasmic ratio
- ◆ Nuclear overlapping, crowding
- ◆ Irregular placement around follicle
- ◆ Nuclear grooving/folding/irregular contour
- ◆ Intranuclear cytoplasmic inclusions
- ◆ Pale chromatin with chromatin  
marginination/condensation and clearing
  - ✓ Orphan Annie Nuclei



# Contour irregularities, folds, grooves

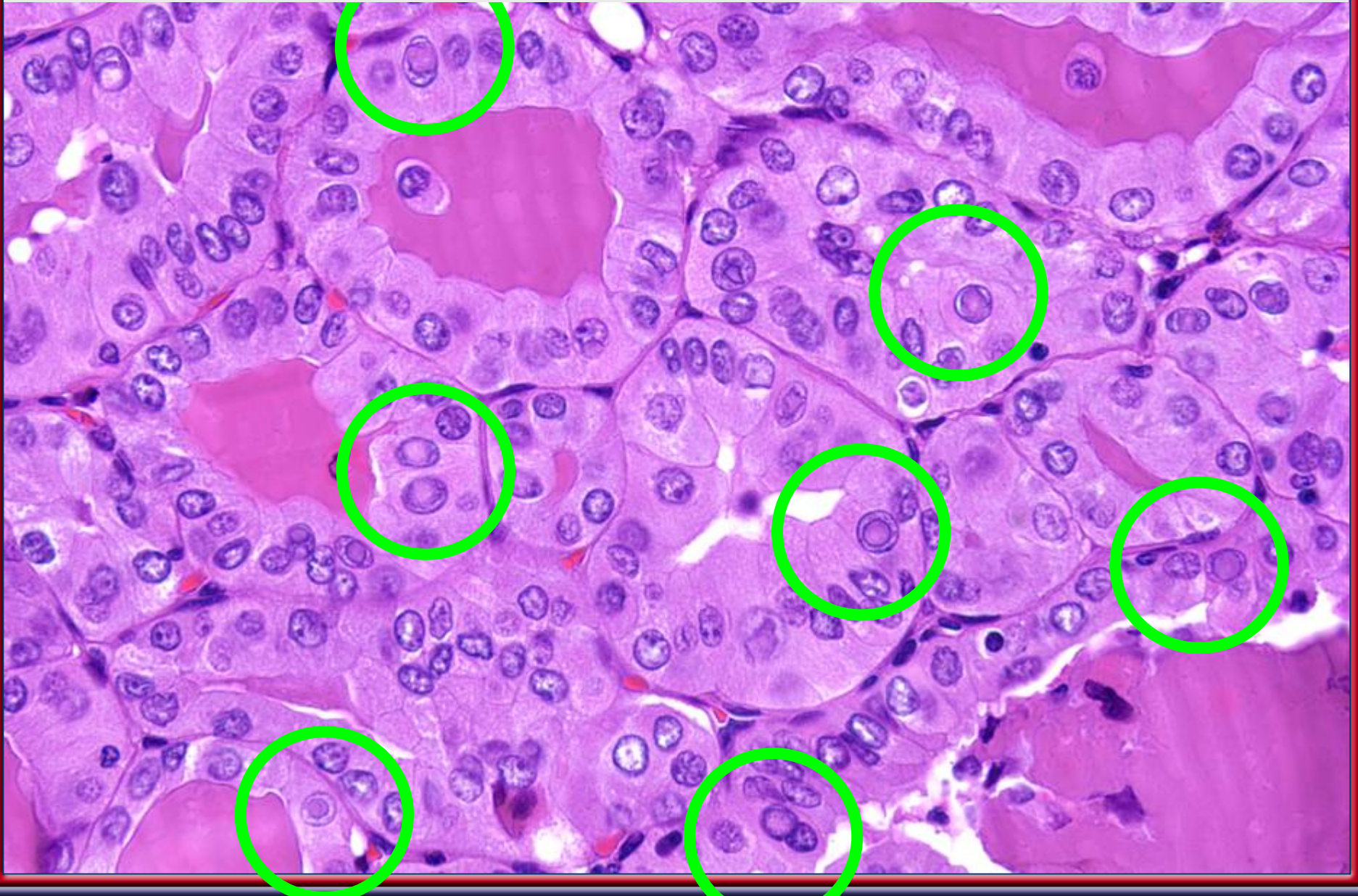


# Nuclear crowding/overlapping; Grooves

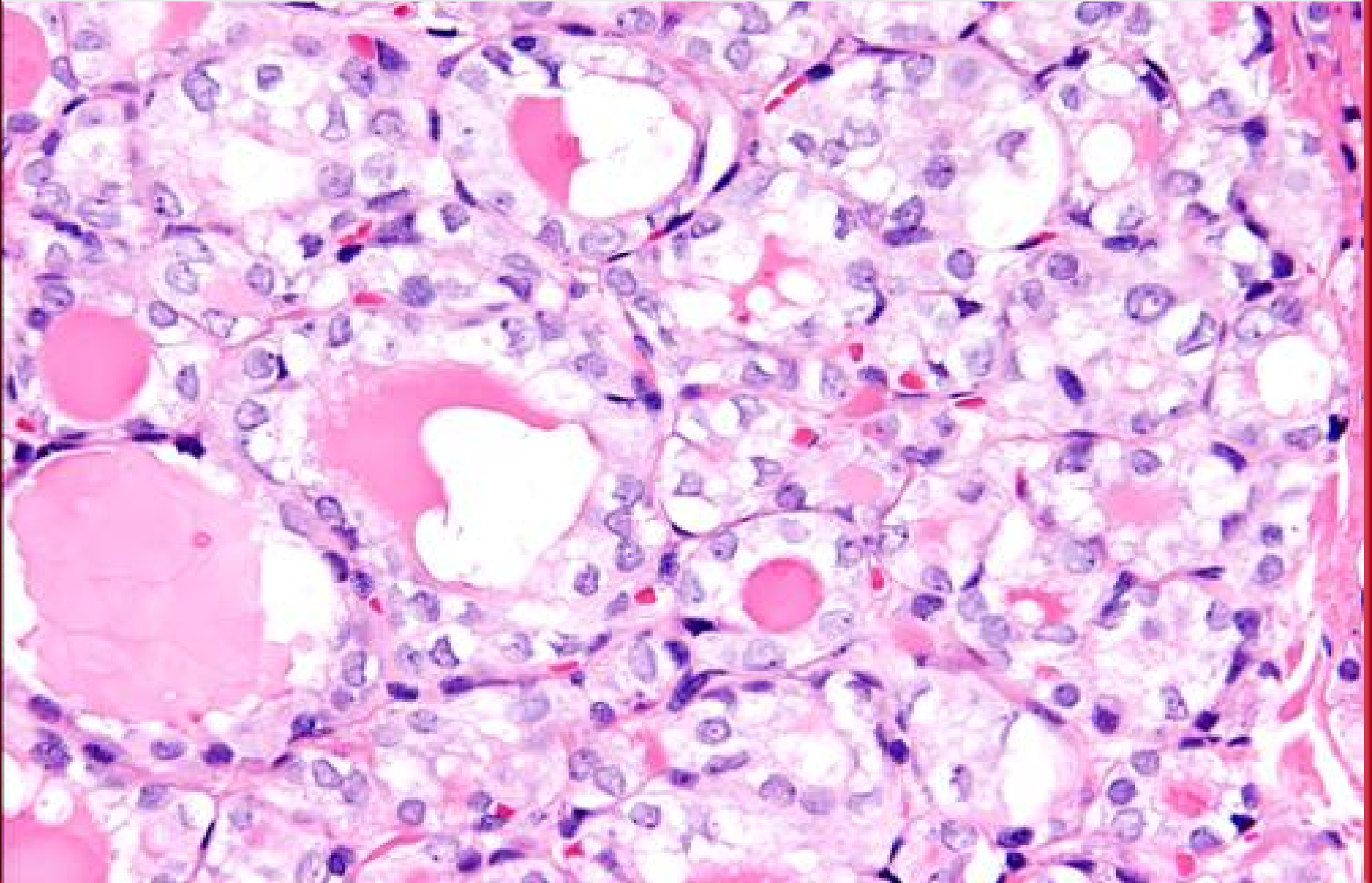




# Intranuclear cytoplasmic inclusions

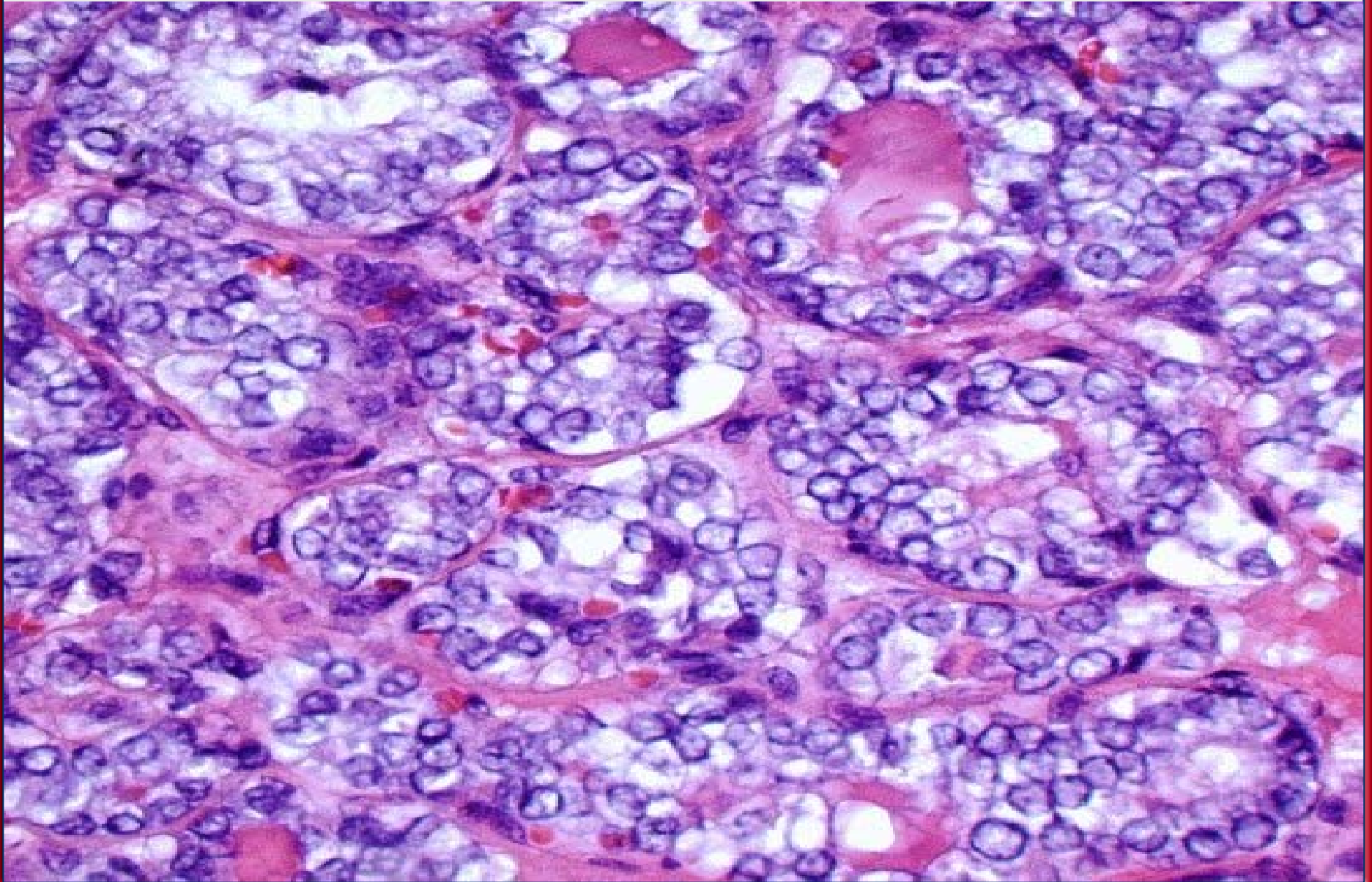


**Delicate, fine, even chromatin**





# Optically clear chromatin in large nuclei



***NIFTP:  
Non-invasive Follicular  
Thyroid Neoplasm with  
Papillary-like Nuclei***

**Accepted term at March, 2015**

***The Endocrine Pathology Society  
Conference for Re-Examination of the  
Encapsulated Follicular Variant of  
Thyroid Papillary Carcinoma  
in Boston***





# Study Design

- International, multi-disciplinary study of 109 patients with non-invasive EFVPTC followed for 10-26 years and 101 patients with invasive EFVPTC followed for 1-18 years collected at 13 sites in 5 countries. Review of digitalized histologic slides by 24 thyroid pathologists from 7 countries.
- 24 experienced thyroid pathologists (representing 7 countries and 4 continents), two endocrinologists, one surgeon, and one psychiatrist. In addition, a molecular pathologist, a biostatistician, and a thyroid cancer survivor/patient advocate participated in the study.

# Study Materials

- A total of 268 tumors diagnosed as EFVPTC based on current criteria were contributed by working group pathologists from 13 institutions
- Potential cases for Group 1 included non-invasive EFVPTC with no radioiodine (RAI) treatment and at least 10 years of follow-up (n=138). Potential cases for Group 2 included EFVPTC with vascular invasion and/or tumor capsule invasion and  $\geq 1$  year of follow-up (n=130).
- 8 week series of weekly teleconferences aimed to refine groups 1 and 2 and to achieve consensus
- <http://image.upmc.edu:8080/NikiForov%20EFV%20Study/view.apml>

*Growth pattern*  
*Nuclear features of PTC*  
*Main oncogene*

Papillary

Yes

BRAF

Papillary  
microCA



Classic  
PTC

Follicular

Yes

RAS

NIFTP



Invasive  
EFVPTC

Follicular

No

RAS

FA



FTC

# Molecular Alterations

- Point mutations involving *RAS* genes about 10% of papillary carcinomas
  - ◆ Almost exclusively the follicular variant
  - ◆ Seen in *NRAS*, *HRAS*, and *KRAS* genes
  - ◆ Strong correlation with
    - ✓ More frequent tumor encapsulation
    - ✓ Lower rate of lymph node
- *BRAF* K601E mutation usually in follicular variant of papillary carcinoma
- *PAX8/PPAR $\gamma$* 
  - ◆ Usually follicular carcinoma
  - ◆ 5% of follicular variant papillary carcinomas

Original Investigation

# Nomenclature Revision for Encapsulated Follicular Variant of Papillary Thyroid Carcinoma

## A Paradigm Shift to Reduce Overtreatment of Indolent Tumors

Yuri E. Nikiforov, MD, PhD; Raja R. Seethala, MD; Giovanni Tallini, MD; Zubair W. Baloch, MD, PhD; Fulvio Basolo, MD; Lester D. R. Thompson, MD; Justine A. Barletta, MD; Bruce M. Wenig, MD; Abir Al Ghuzlan, MD; Kennichi Kakudo, MD, PhD; Thomas J. Giordano, MD, PhD; Venancio A. Alves, MD, PhD; Elham Khanafshar, MD, MS; Sylvia L. Asa, MD, PhD; Adel K. El-Naggar, MD; William E. Gooding, MS; Steven P. Hodak, MD; Ricardo V. Lloyd, MD, PhD; Guy Maytal, MD; Ozgur Mete, MD; Marina N. Nikiforova, MD; Vania Nosé, MD, PhD; Mauro Papotti, MD; David N. Poller, MB, ChB, MD, FRCPath; Peter M. Sadow, MD, PhD; Arthur S. Tischler, MD; R. Michael Tuttle, MD; Kathryn B. Wall; Virginia A. LiVolsi, MD; Gregory W. Randolph, MD; Ronald A. Ghossein, MD

**IMPORTANCE** Although growing evidence points to highly indolent behavior of encapsulated follicular variant of papillary thyroid carcinoma (EFVPTC), most patients with EFVPTC are treated as having conventional thyroid cancer.

*JAMA Oncol.* doi:10.1001/jamaoncol.2016.0386

Published online April 14, 2016.

← Editorial

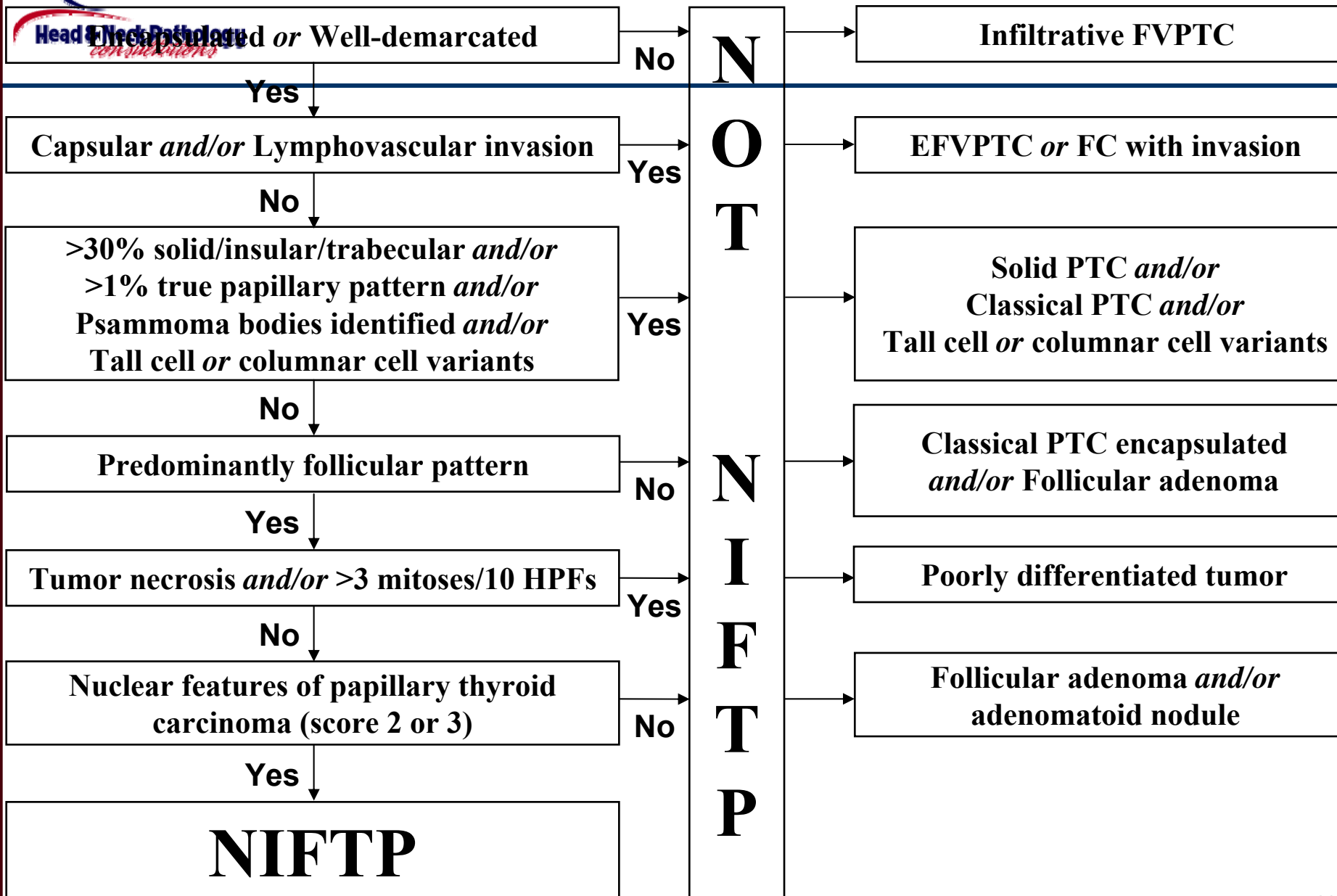
+ Supplemental content at  
[jamaoncol.com](http://jamaoncol.com)



# Criteria

Major Features	Minor Features	Features not seen/ Exclusion criteria
<ol style="list-style-type: none"> <li>1. Encapsulation or clear demarcation</li> <li>2. Follicular growth pattern (&lt;1% papillae)</li> <li>3. Nuclear Features of PTC (Score 2 or 3): <ul style="list-style-type: none"> <li>• Enlargement/crowding/overlapping</li> <li>• Elongation</li> <li>• Irregular contours</li> <li>• Grooves</li> <li>• Pseudoinclusions</li> <li>• Chromatin clearing</li> </ul> </li> </ol>	<ol style="list-style-type: none"> <li>1. Dark colloid</li> <li>2. Irregularly-shaped follicles</li> <li>3. Intratumoral fibrosis</li> <li>4. “Sprinkling” sign</li> <li>5. Follicles cleft from stroma</li> <li>6. Multinucleated giant cells within follicles</li> </ol>	<ol style="list-style-type: none"> <li>1. “True” papillae &gt;1%</li> <li>2. Psammoma bodies</li> <li>3. Infiltrative border (capsular or lymphovascular invasion)</li> <li>4. Tumor necrosis</li> <li>5. High mitotic activity (&gt;3/10 HPFs)</li> <li>6. Cell/morphologic characteristics of other variants of PTC</li> </ol>

# ALGORITHM FOR DIAGNOSIS OF NIFTP

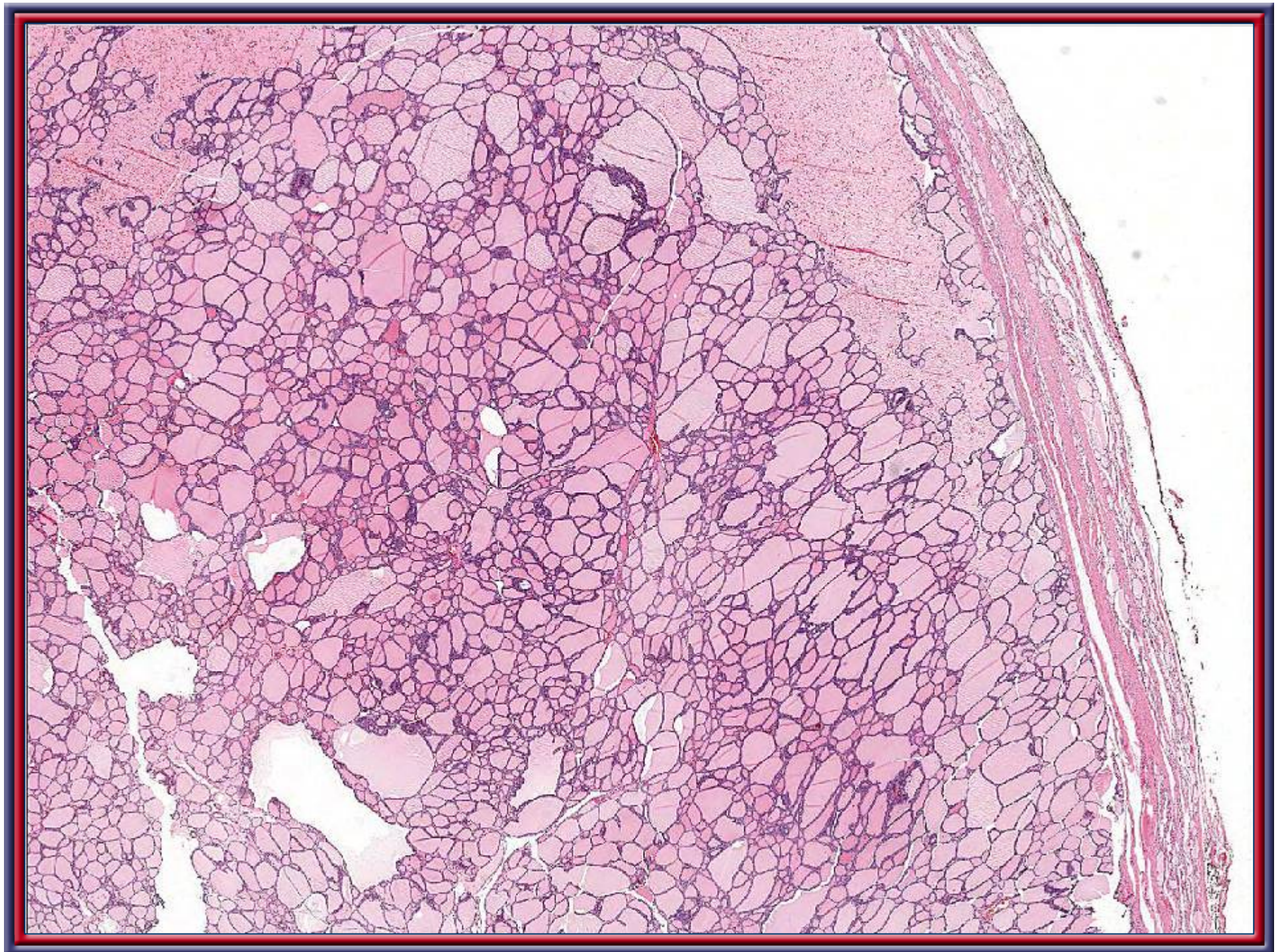




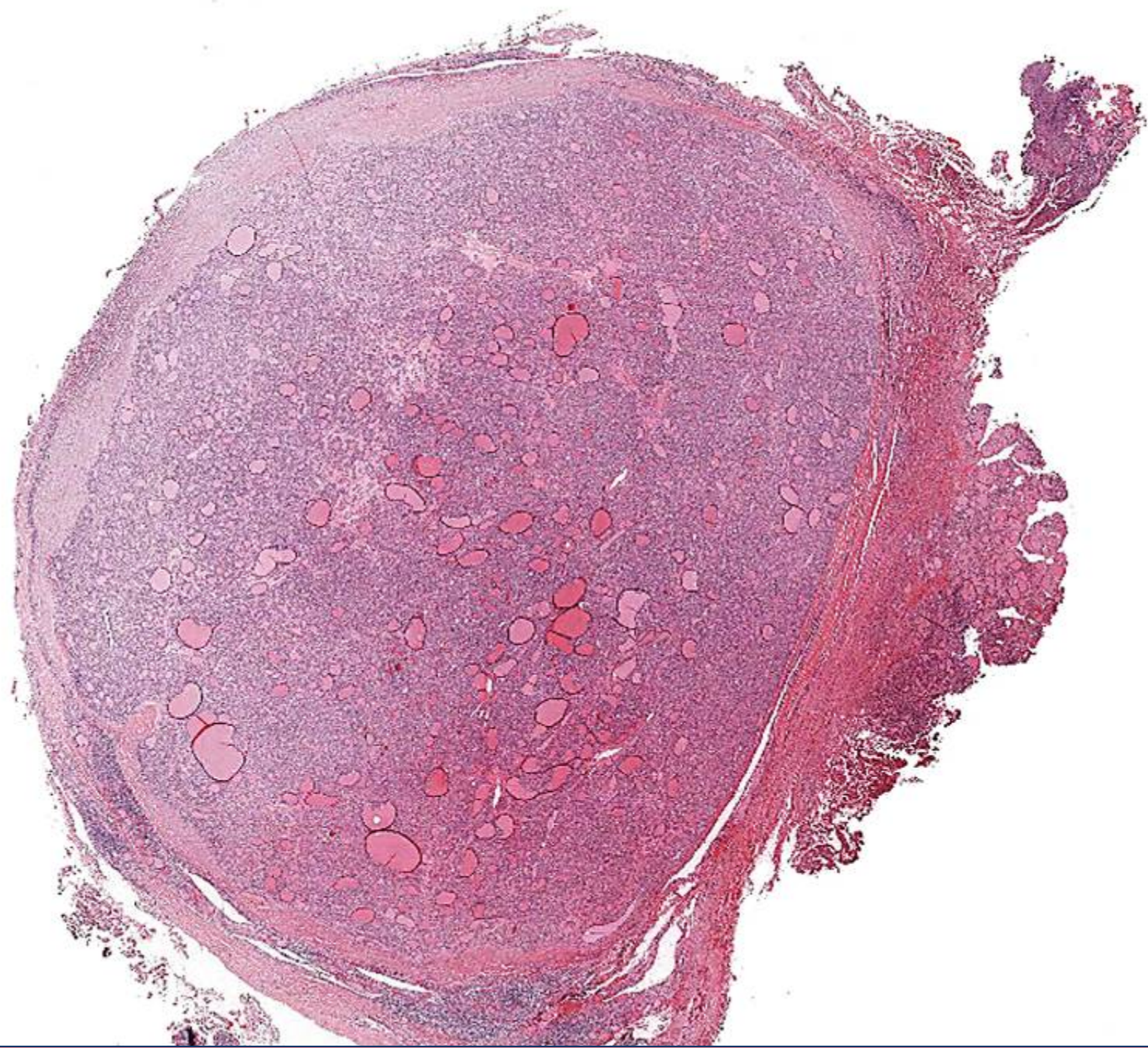
## Non-invasive Follicular Thyroid Neoplasm with Papillary-like Nuclei

- **Surrounded by thick, well formed capsule**
  - ◆ Capsule may be thinned and attenuated
  - ◆ Partially encapsulated and incompletely encapsulated are equivalent
  - ◆ Smooth muscle-walled vessels within the fibrosis

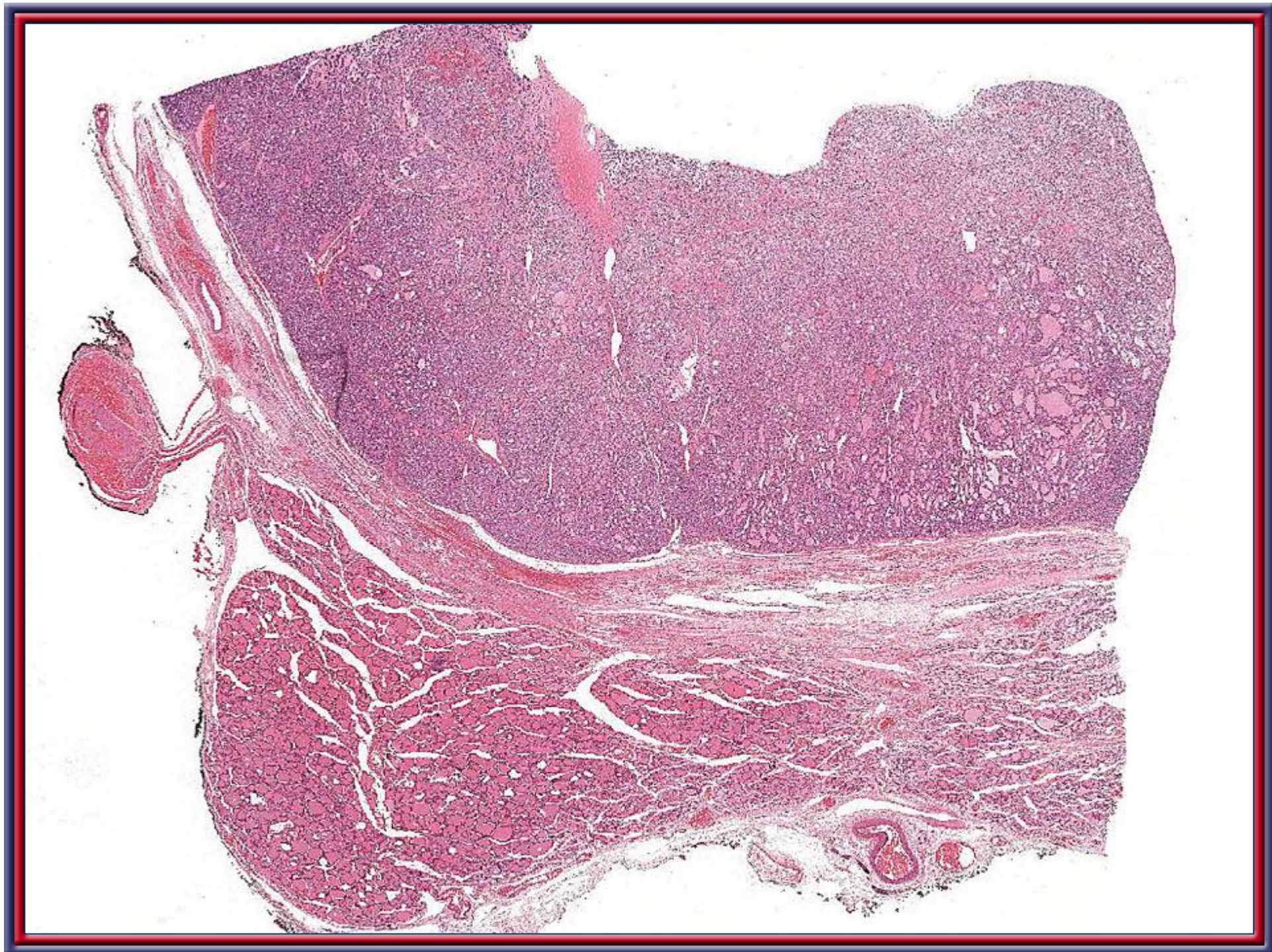




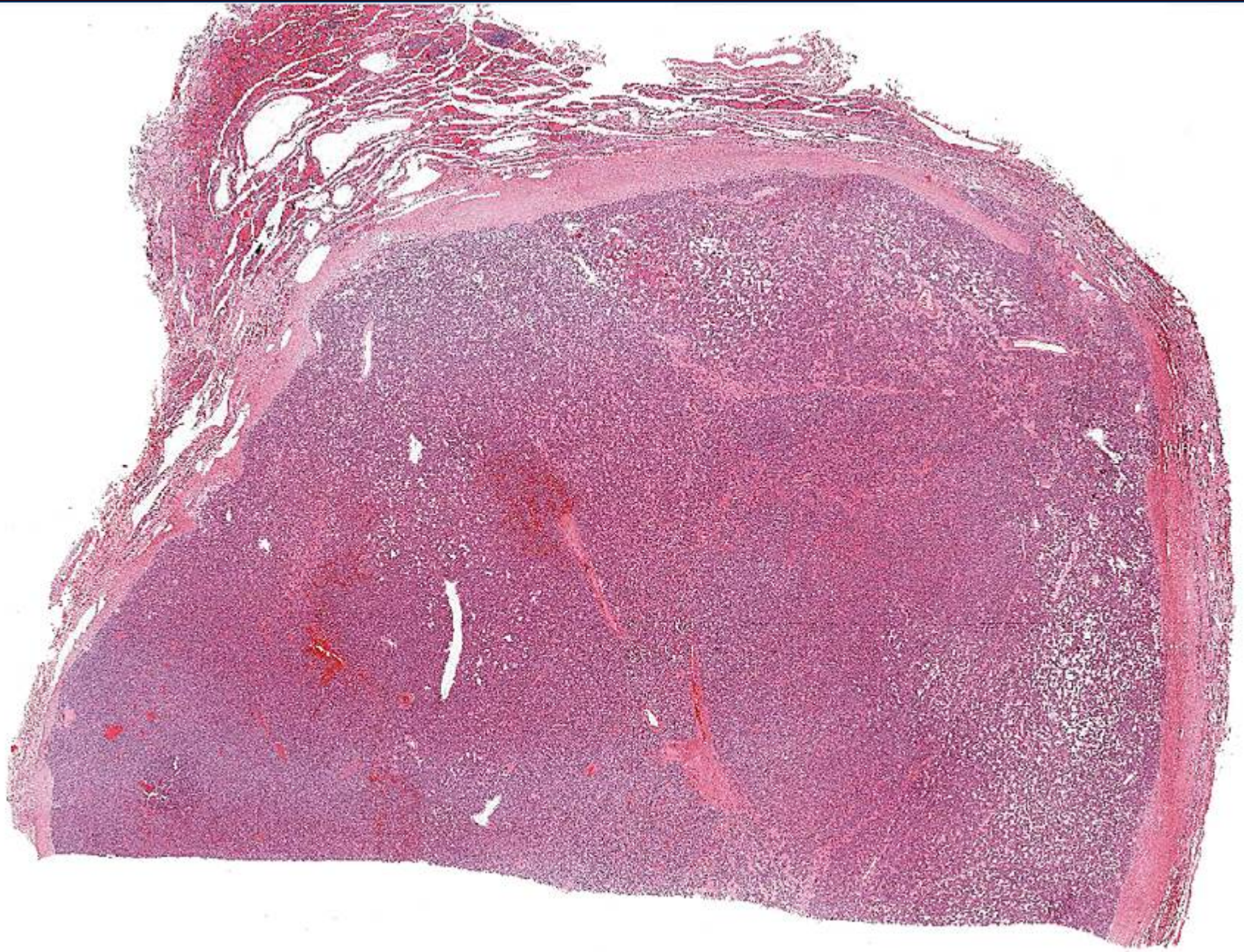




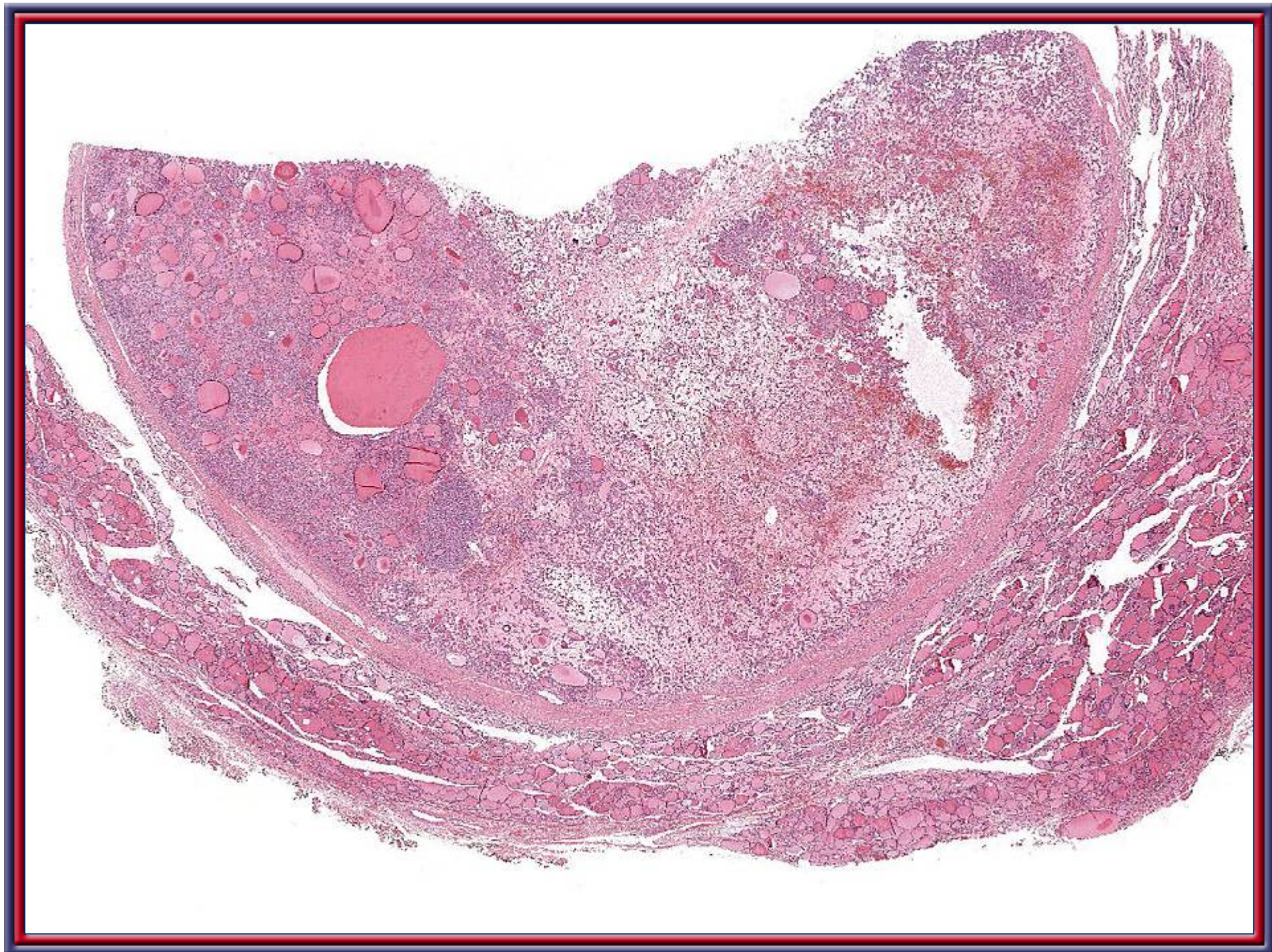






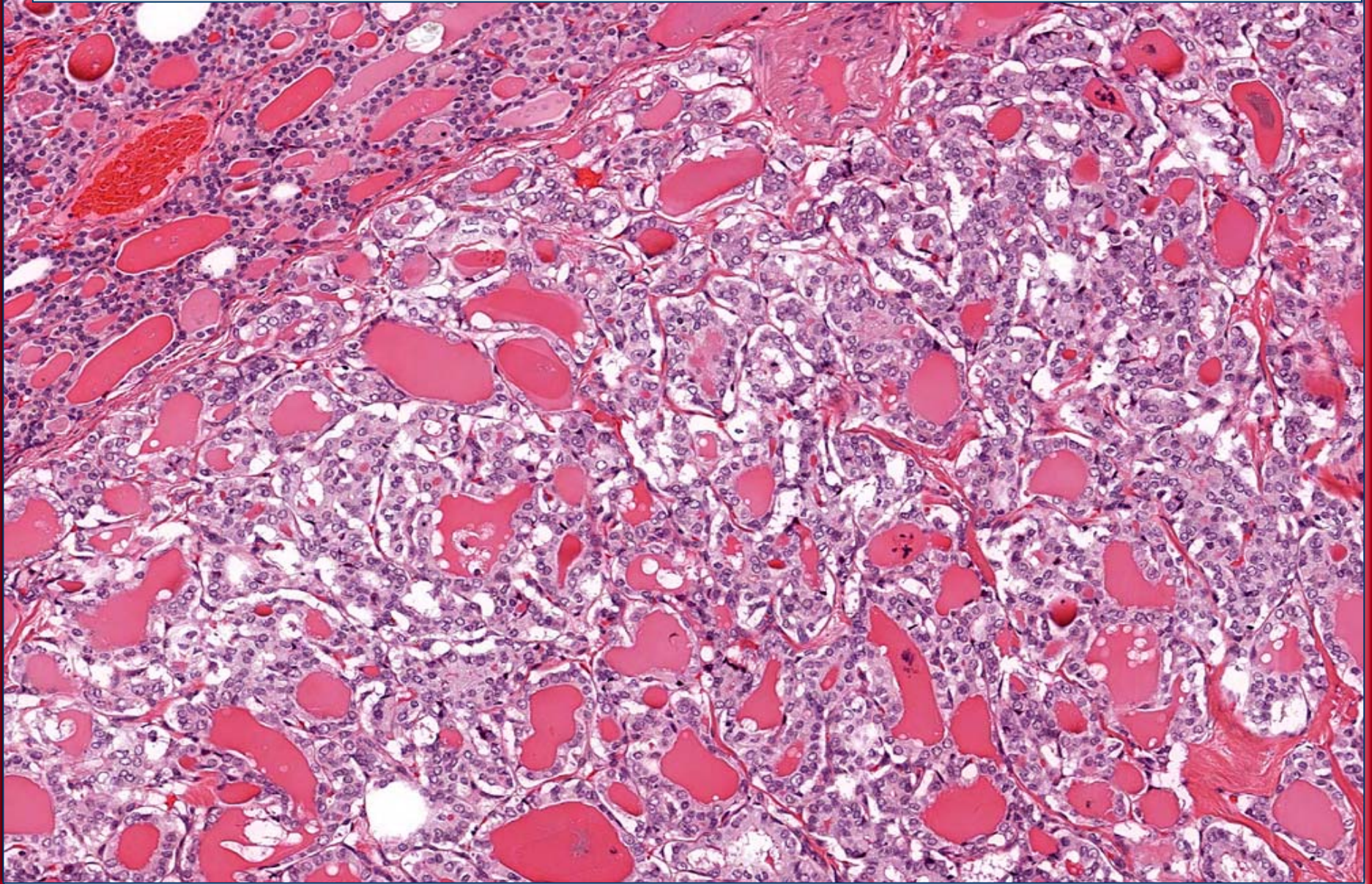








**Partially encapsulated—circumscribed**

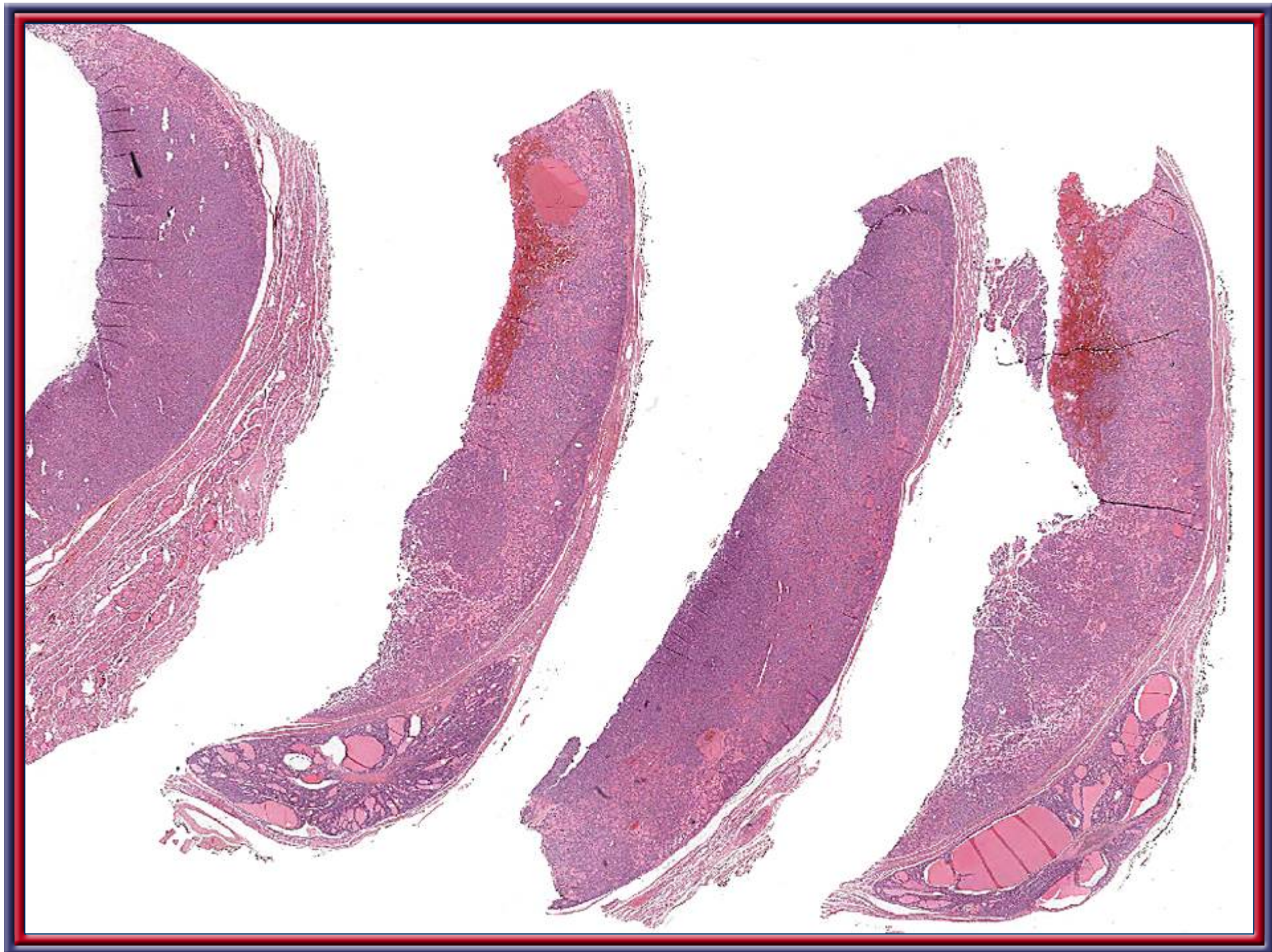




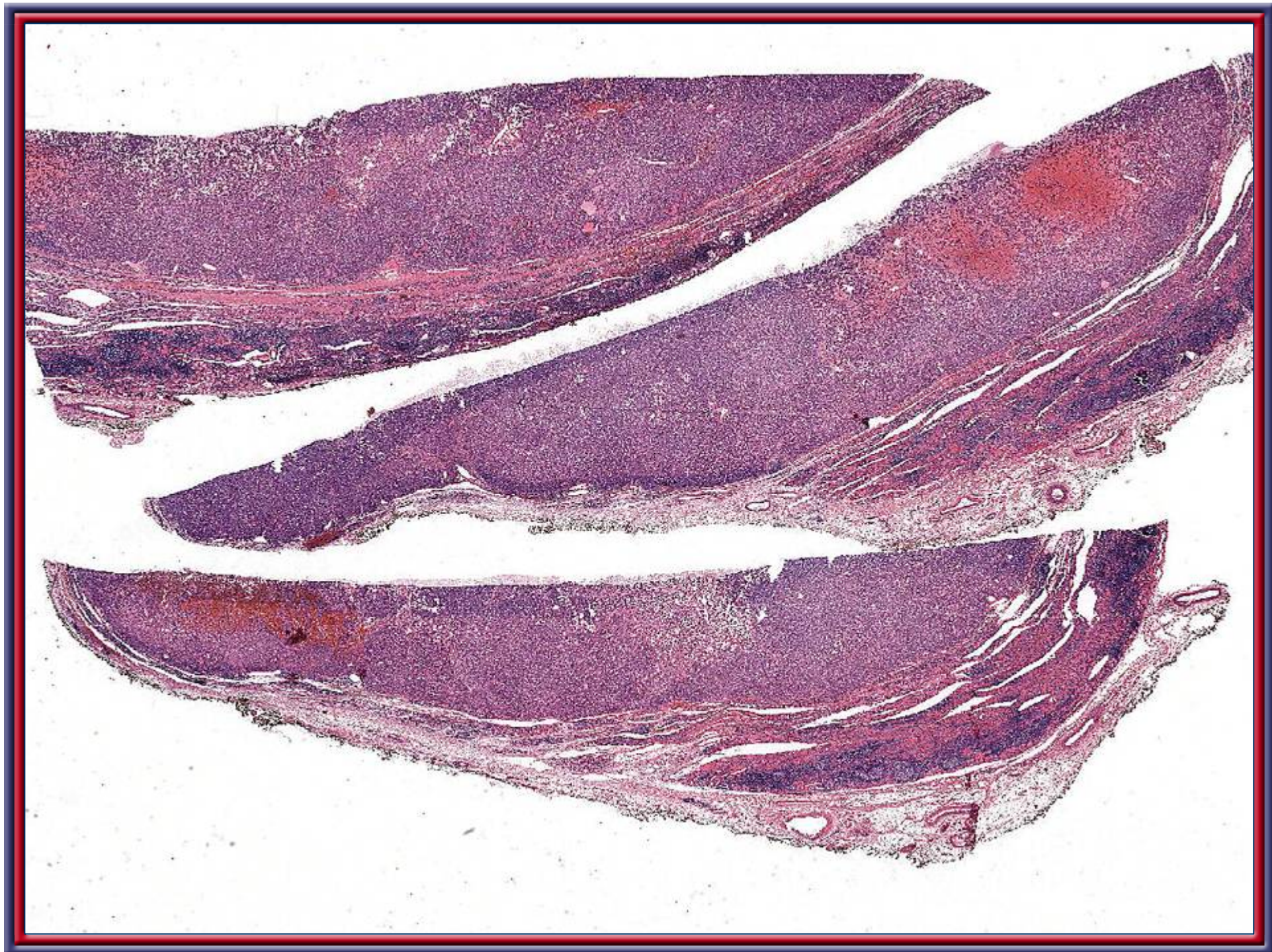
# Non-invasive Follicular Thyroid Neoplasm with Papillary-like Nuclei

- Absent invasion
- By definition this must be “non-invasive”
  - ◆ No capsular invasion
  - ◆ No vascular invasion
- Must be adequately (completely) sampled
  - ◆ Tumor to capsule to parenchyma
  - ◆ 3 sections (not blocks) per cm of tumor



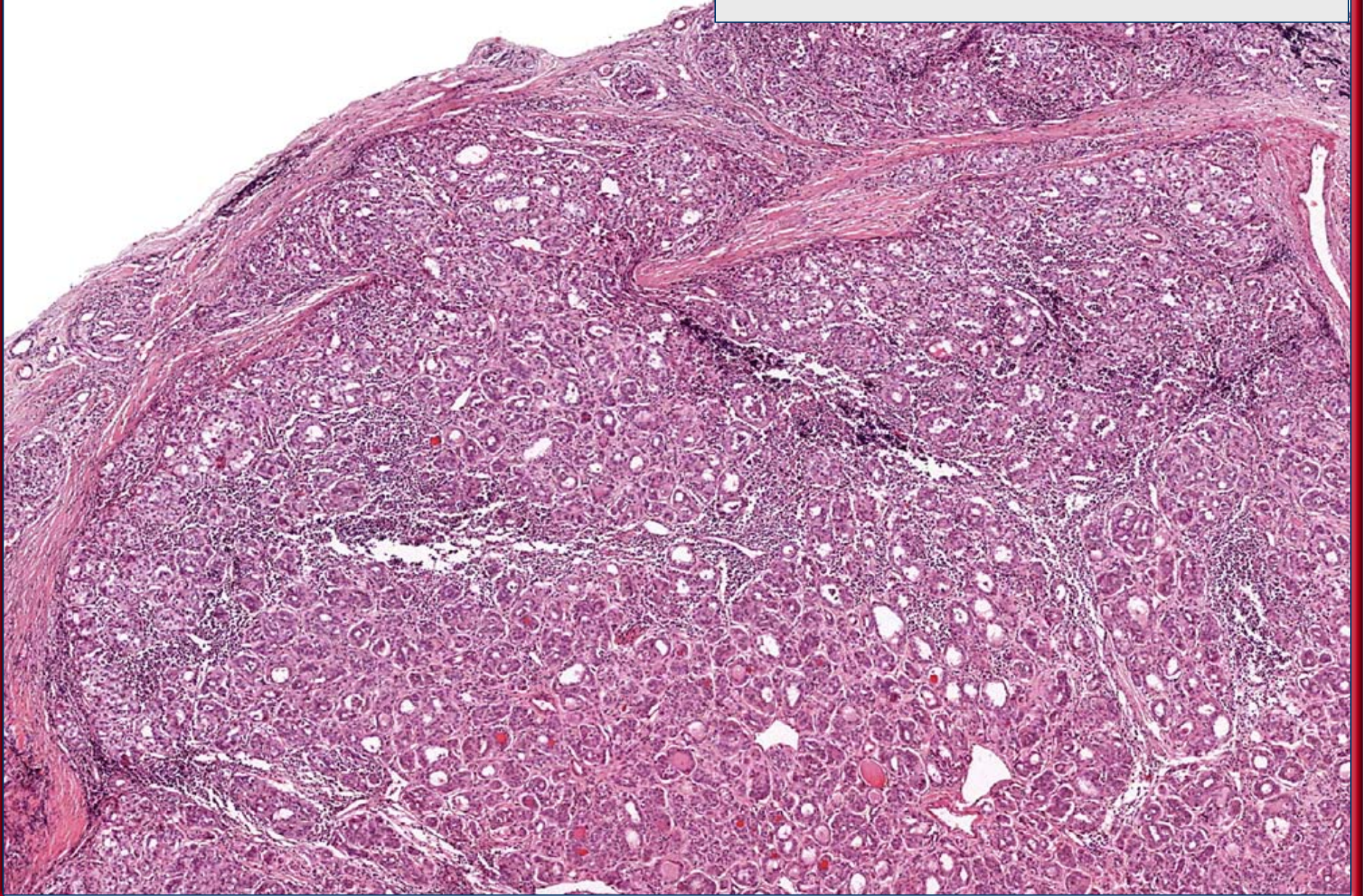






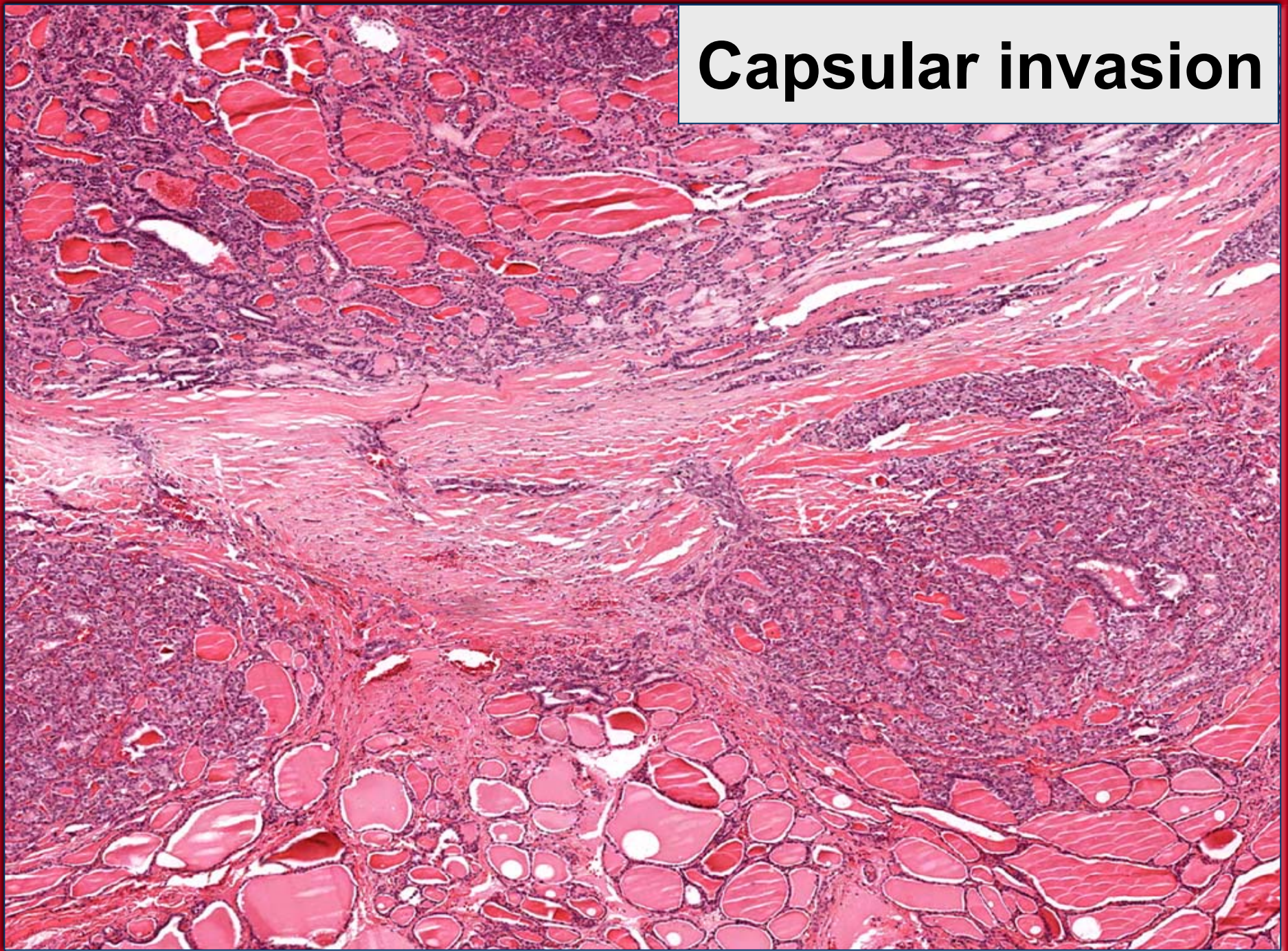


# Capsular invasion



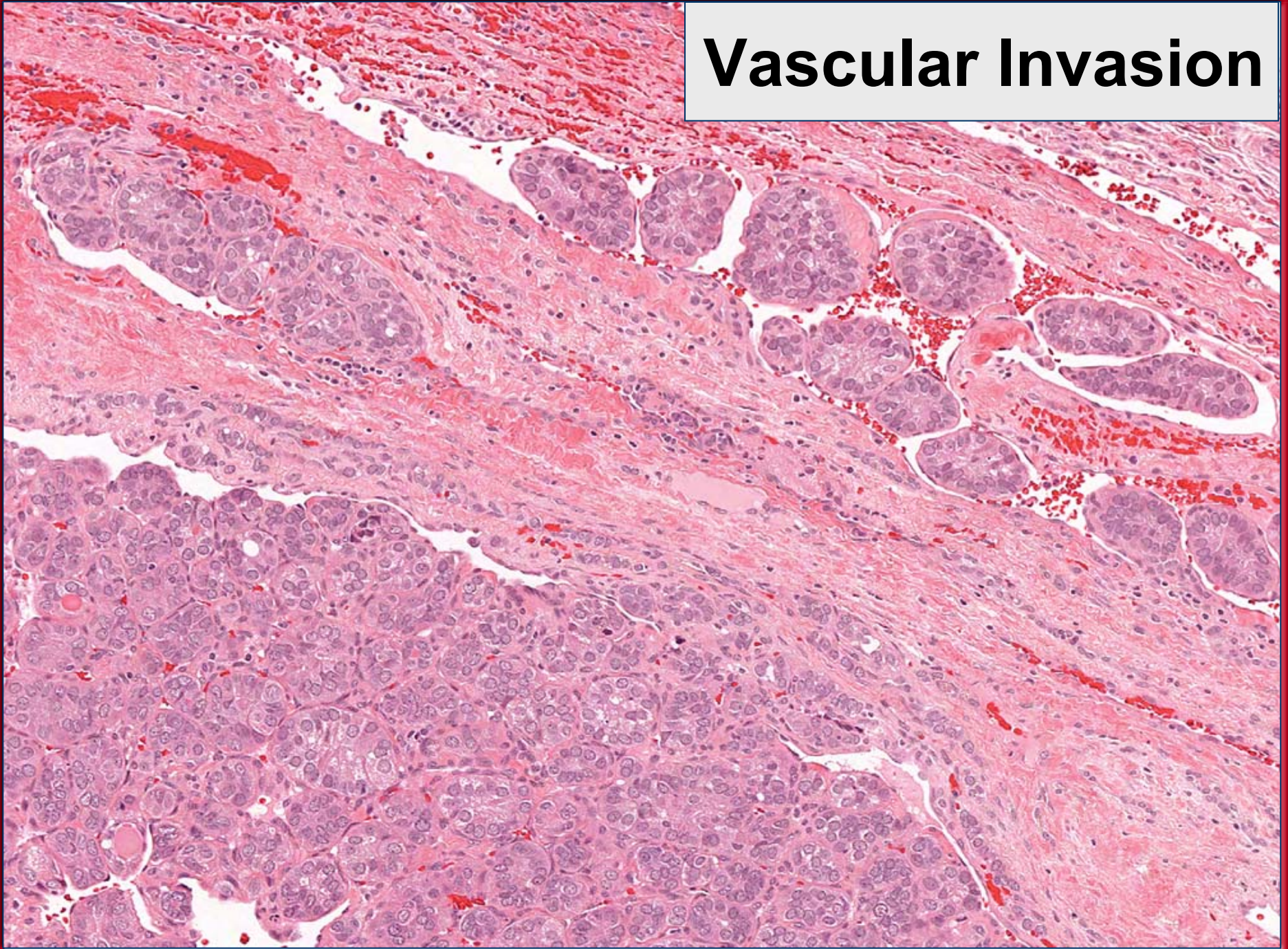


# Capsular invasion





# Vascular Invasion

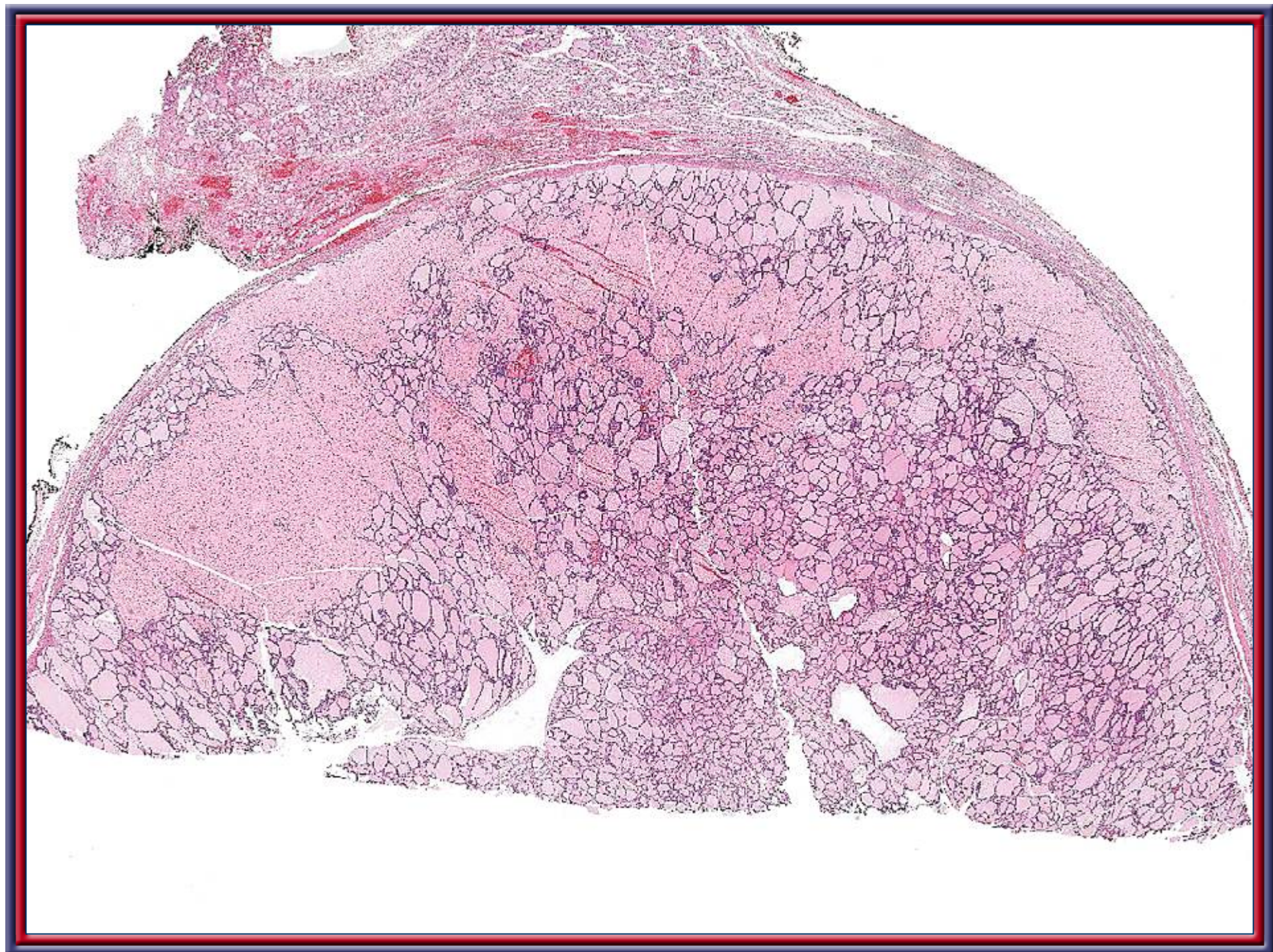




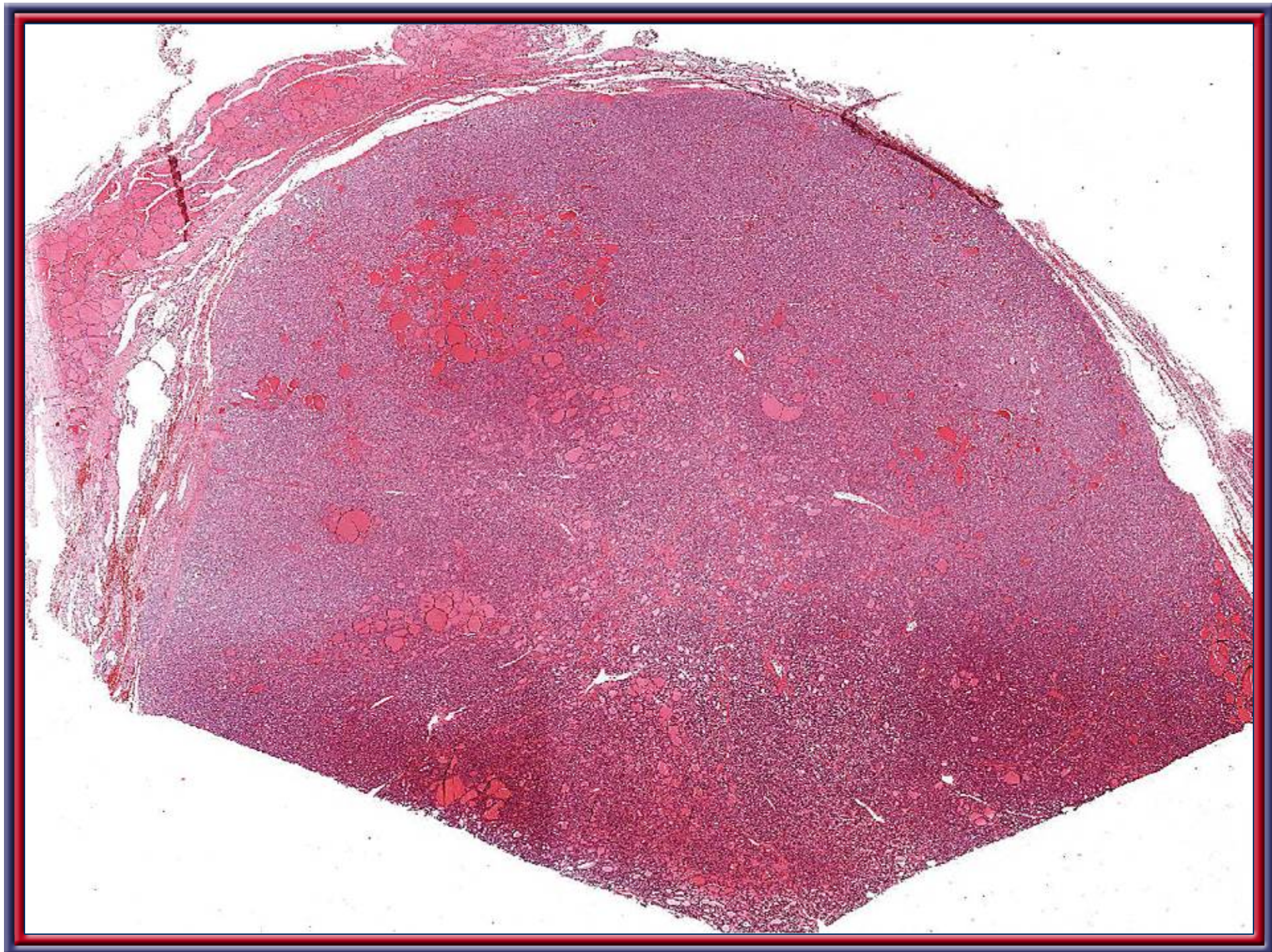
# Noninvasive Follicular Thyroid Neoplasm with Papillary-like Nuclei

- **Predominantly follicular pattern of growth**
  - ◆ **Small to medium, round, twisted and elongated follicles**
  - ◆ **Follicles are often a monotonous size and shape (helpful feature)**
  - ◆ **Isolated or rare papillae may be seen**
    - ✓ **Must be  $\leq 1\%$  of overall tumor volume**
    - ✓ **If  $>1\%$ , then it is NOT follicular variant**

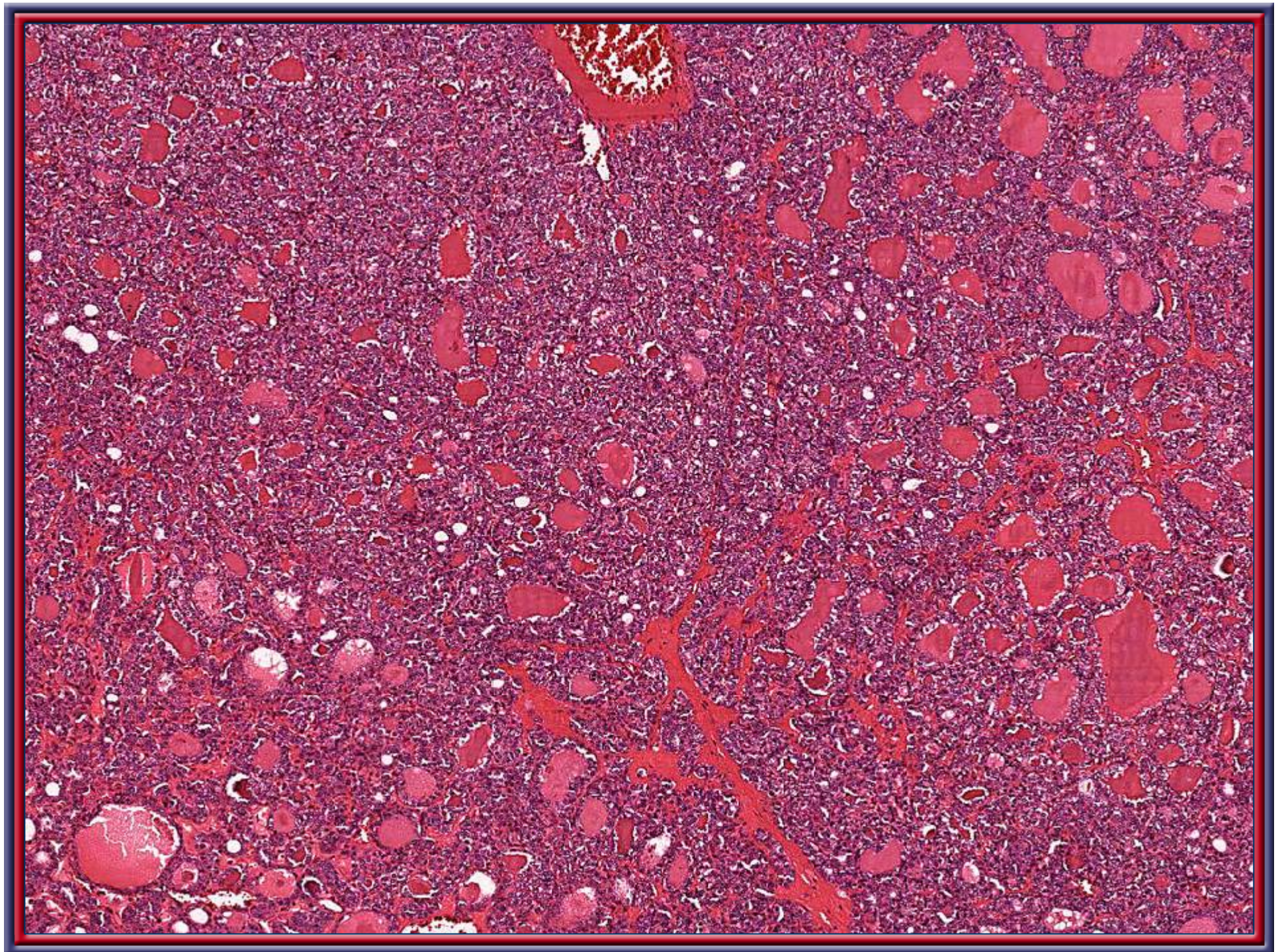




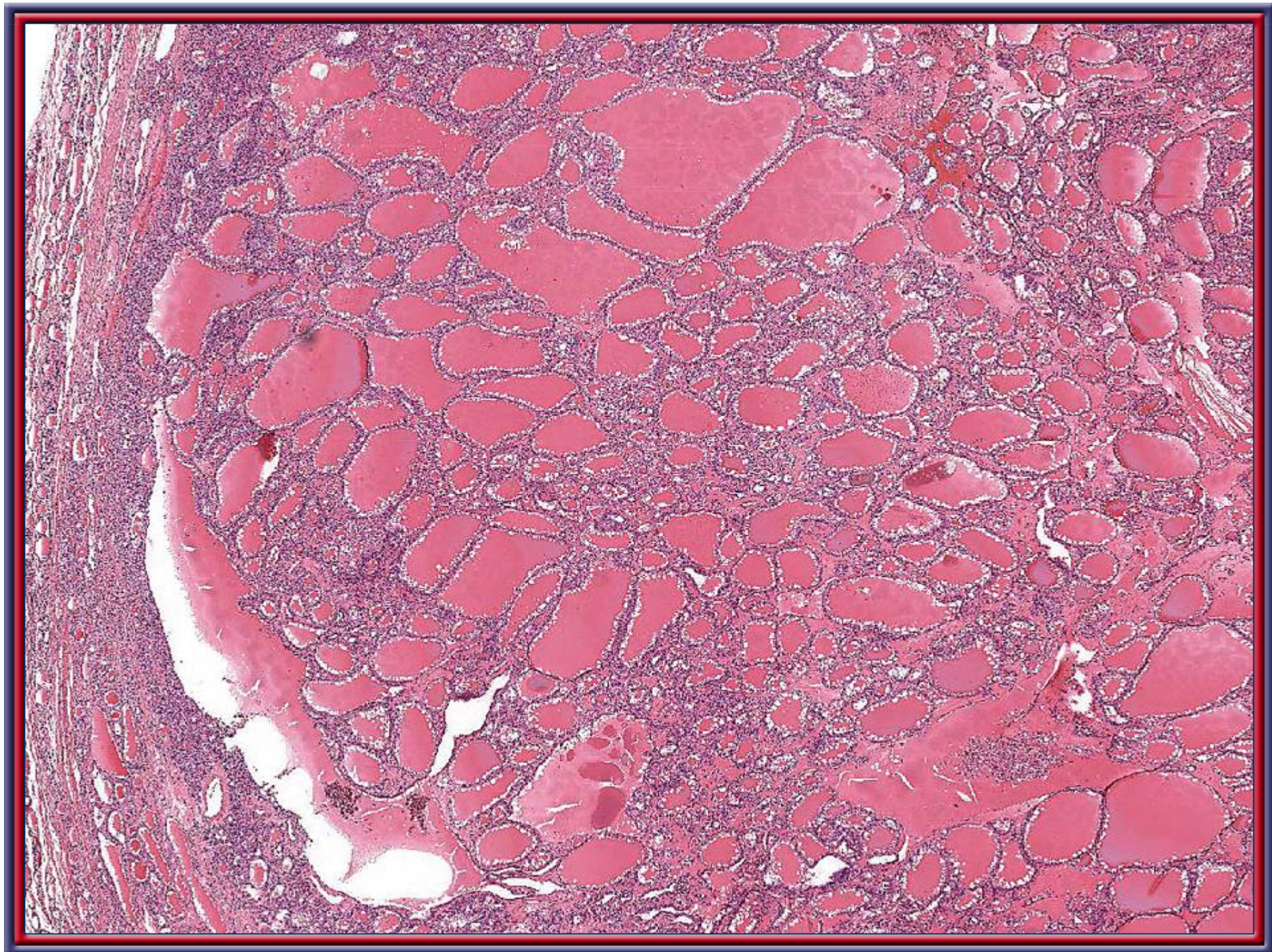






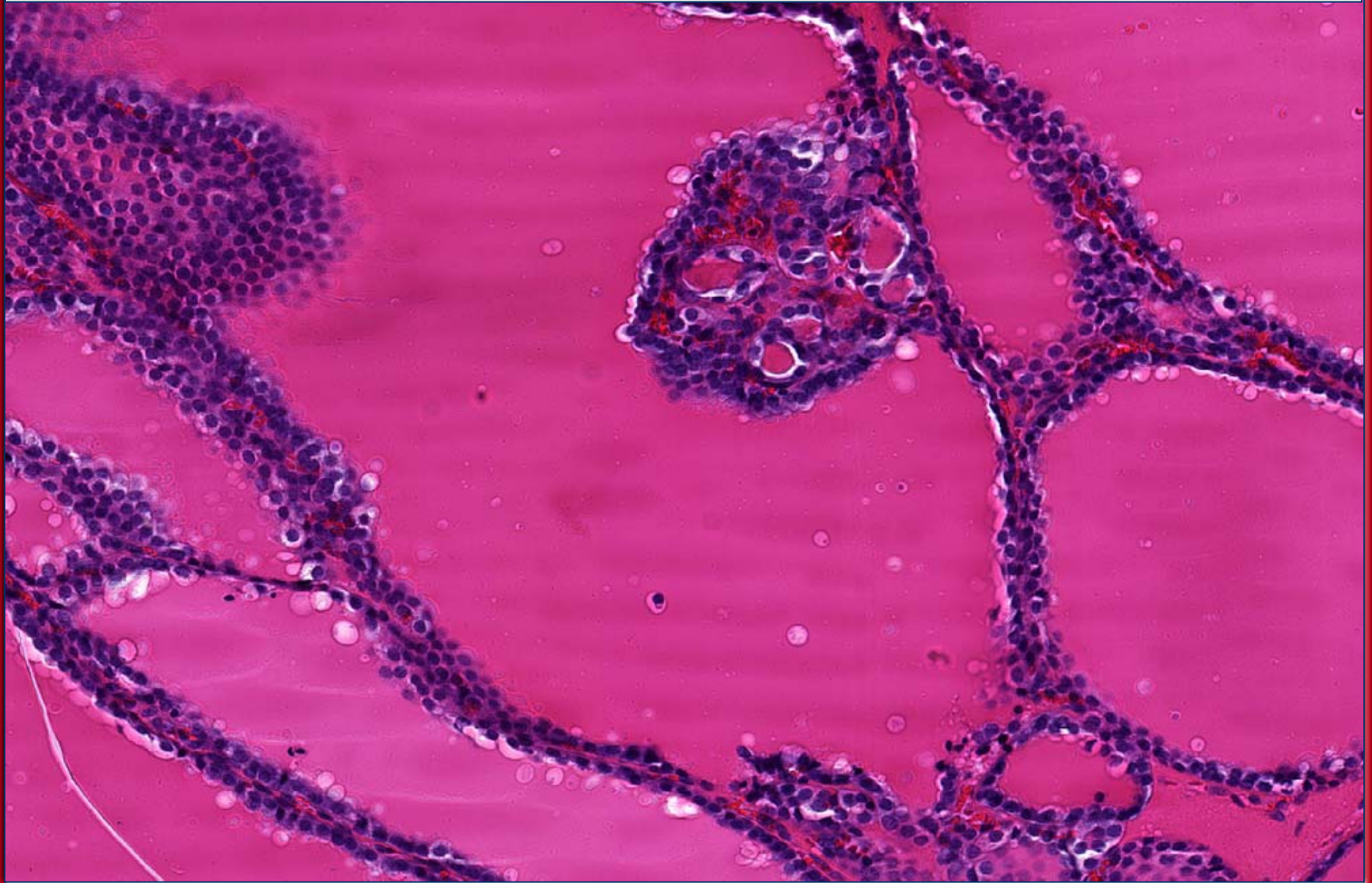






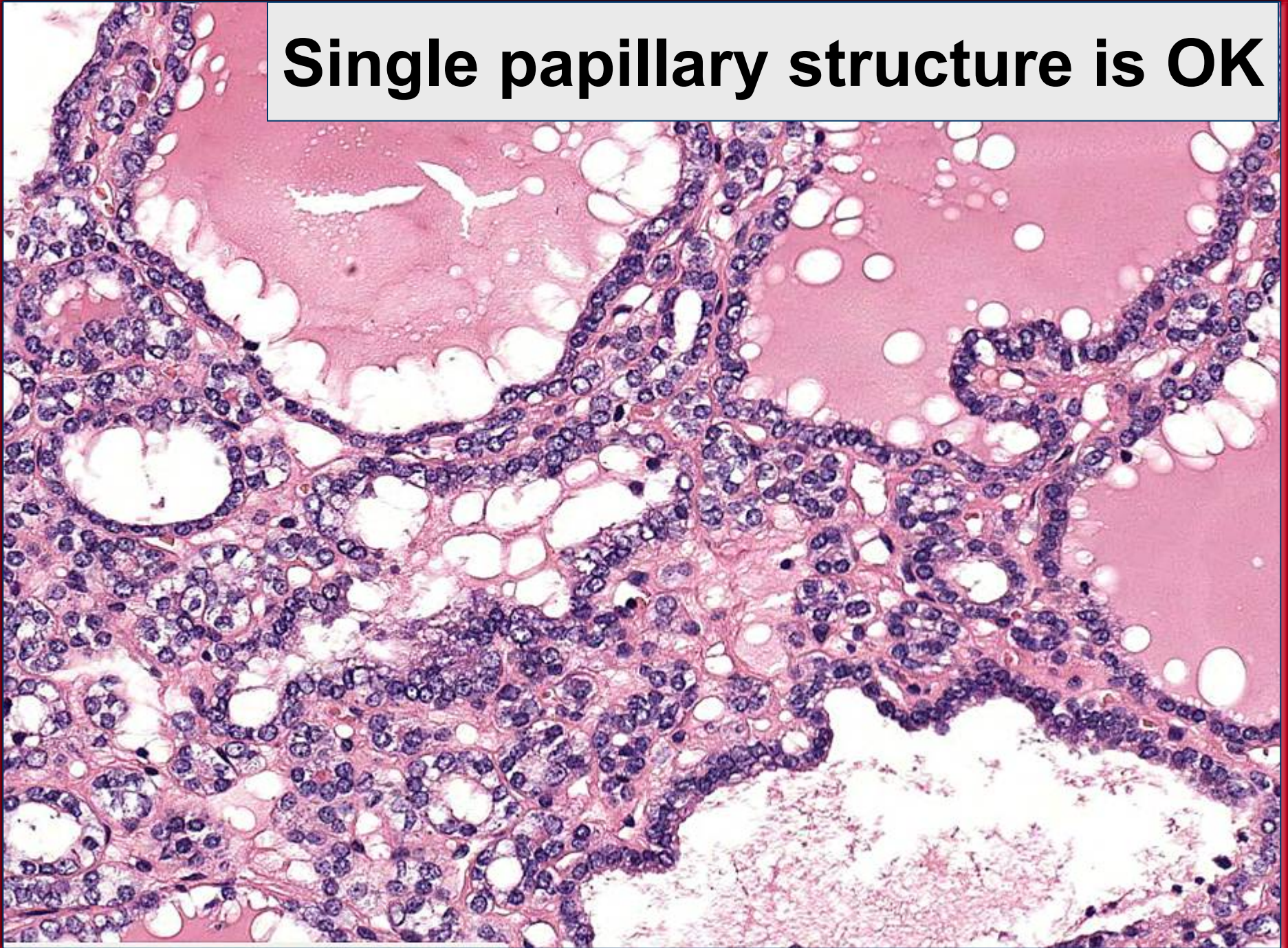


# Sandison pseudopapillary structure OK



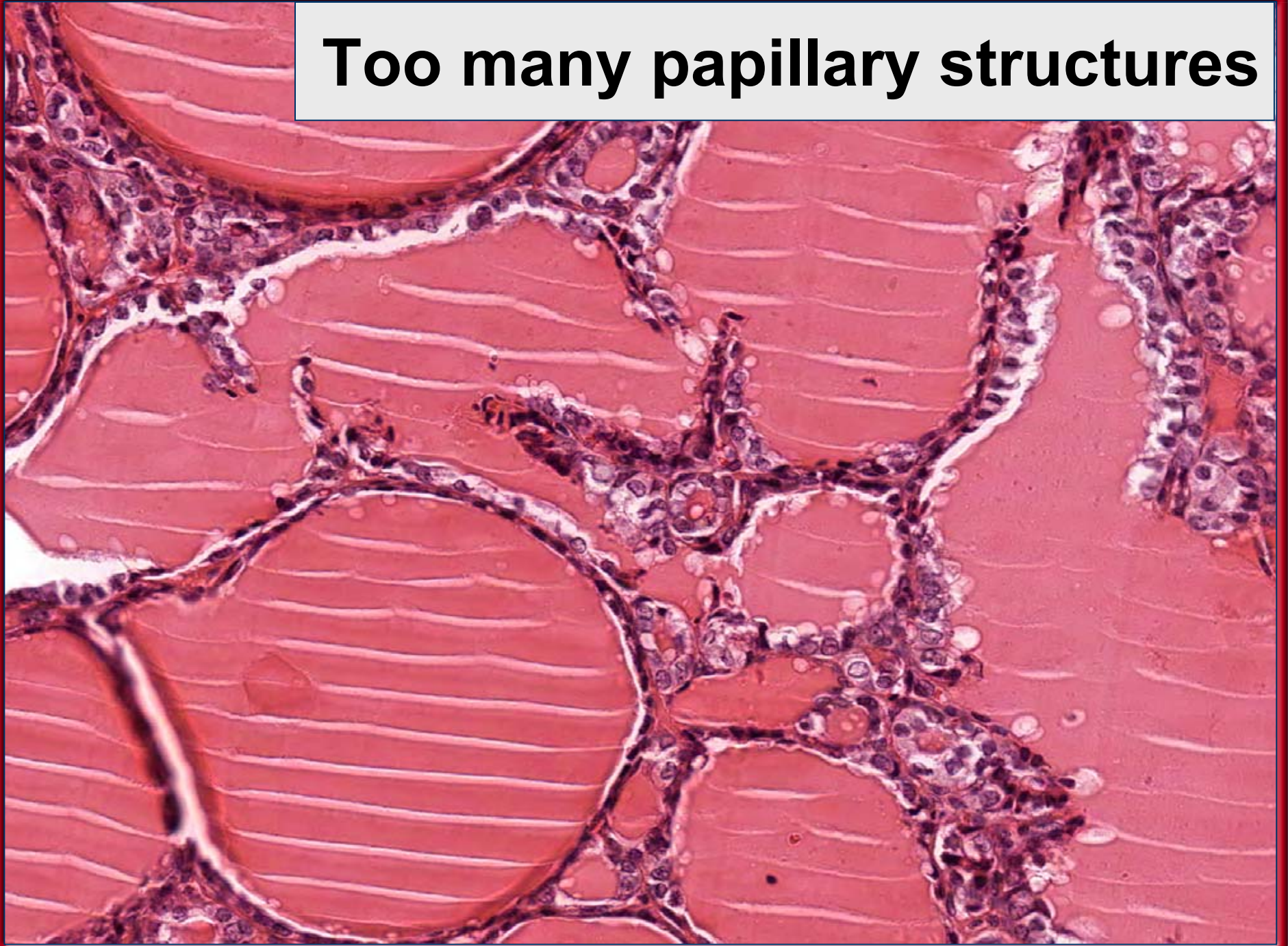


**Single papillary structure is OK**



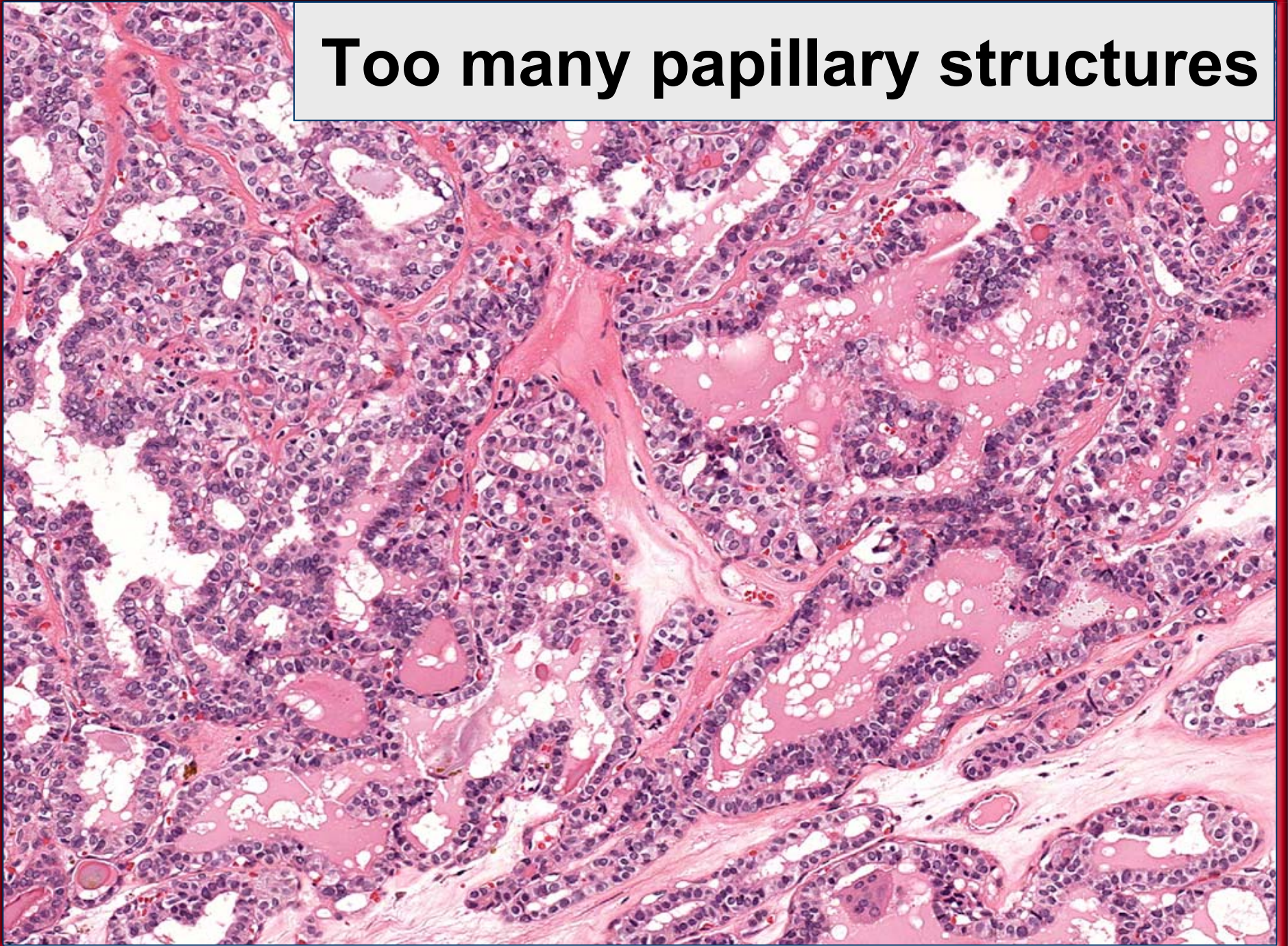


**Too many papillary structures**





**Too many papillary structures**



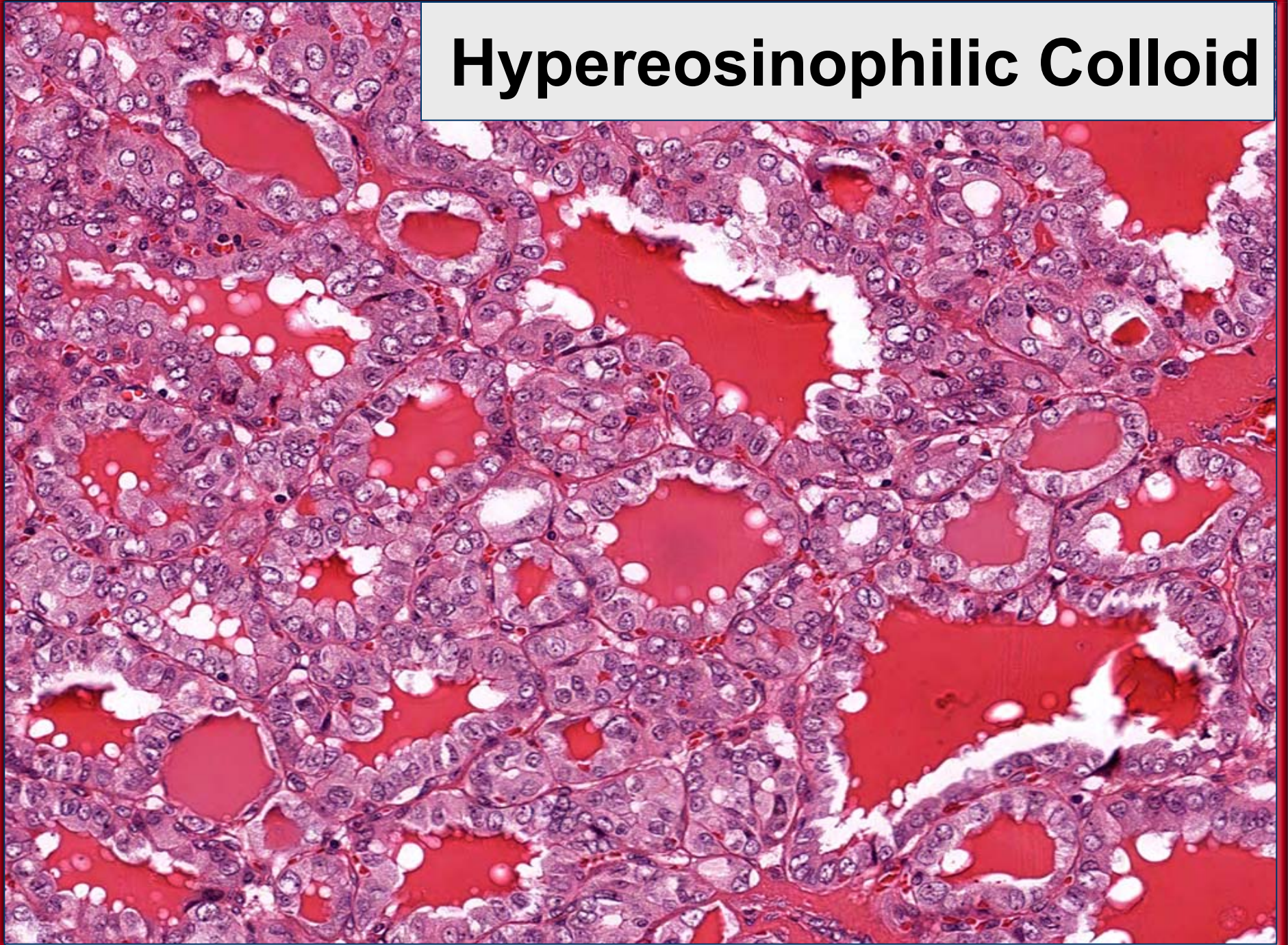


## Non-invasive Follicular Thyroid Neoplasm with Papillary-like Nuclei

- Hypereosinophilic colloid
- Scalloped colloid frequently present
- Internal, acellular, eosinophilic fibrosis between follicles
  - ◆ Dropping substage often creates a “bright” signal

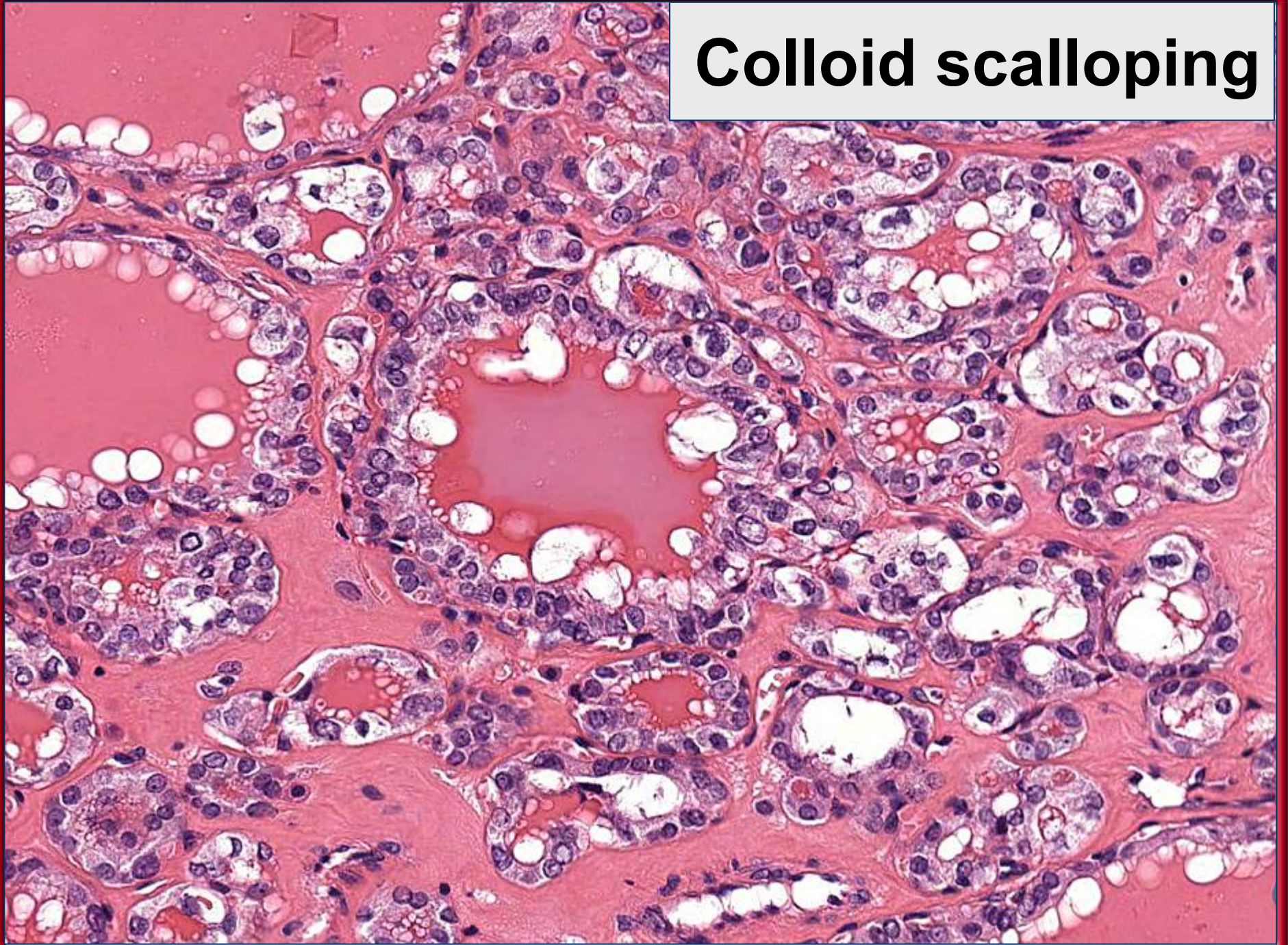


# Hypereosinophilic Colloid



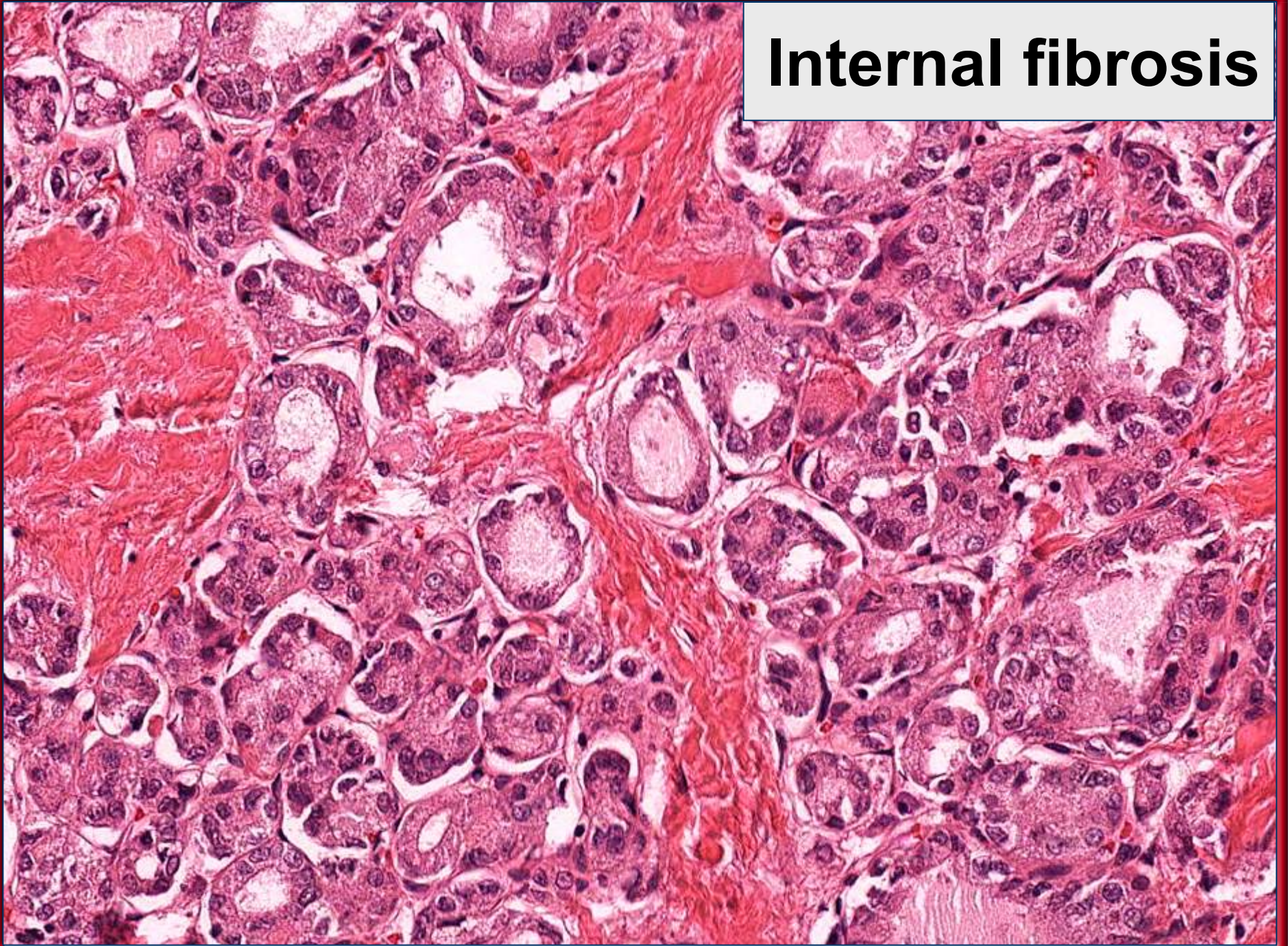


# Colloid scalloping





# Internal fibrosis



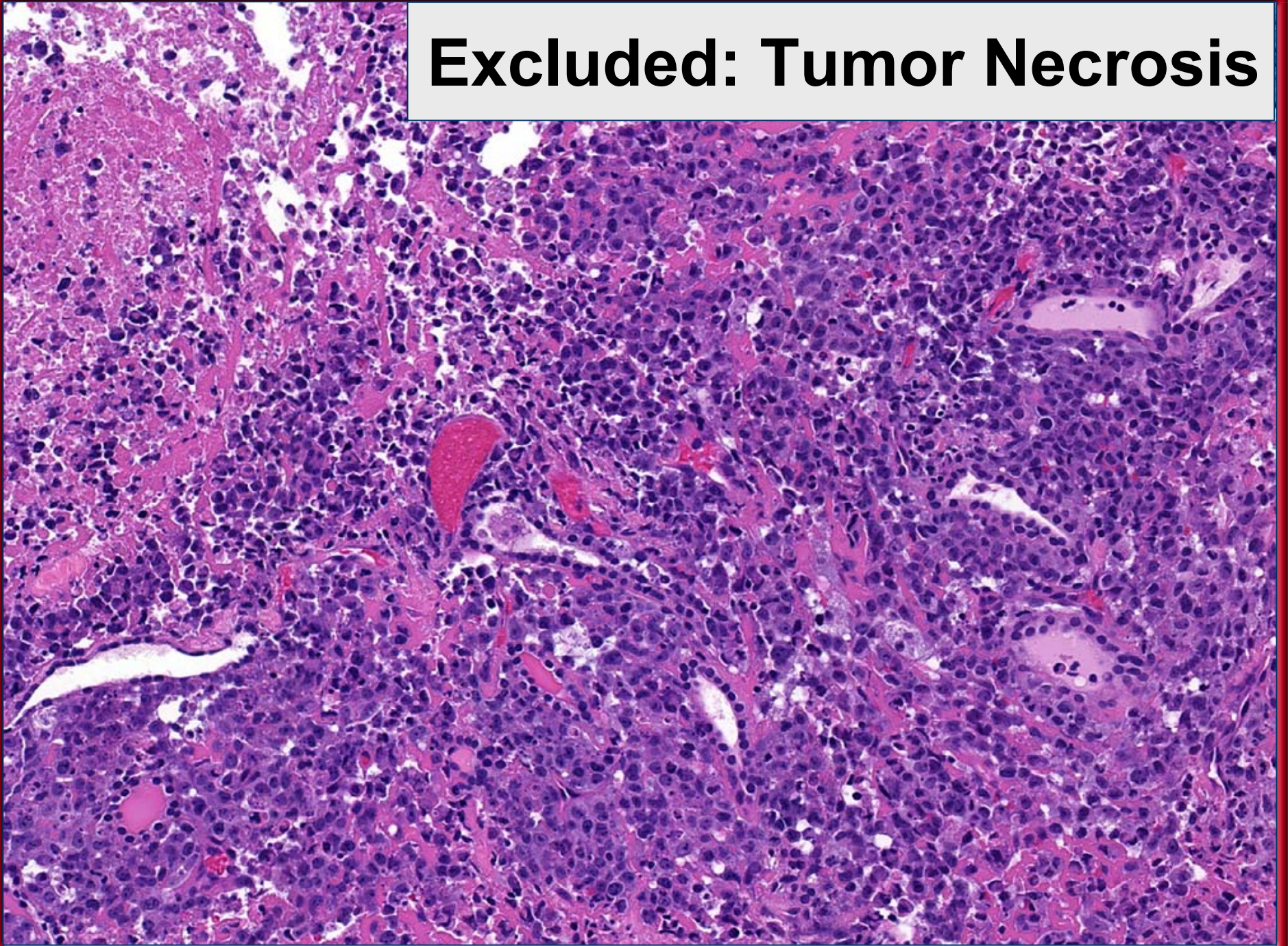


## Noninvasive Follicular Thyroid Neoplasm with Papillary-like Nuclei

- Absent psammoma bodies
- Absent necrosis
- No increased mitoses
  - ◆  $\leq 3$  mitoses/10 High Power Fields
- No other patterns or specific tumor types present
  - ◆ Solid, insular, trabecular, morular
  - ◆ Oncocytic, tall, columnar

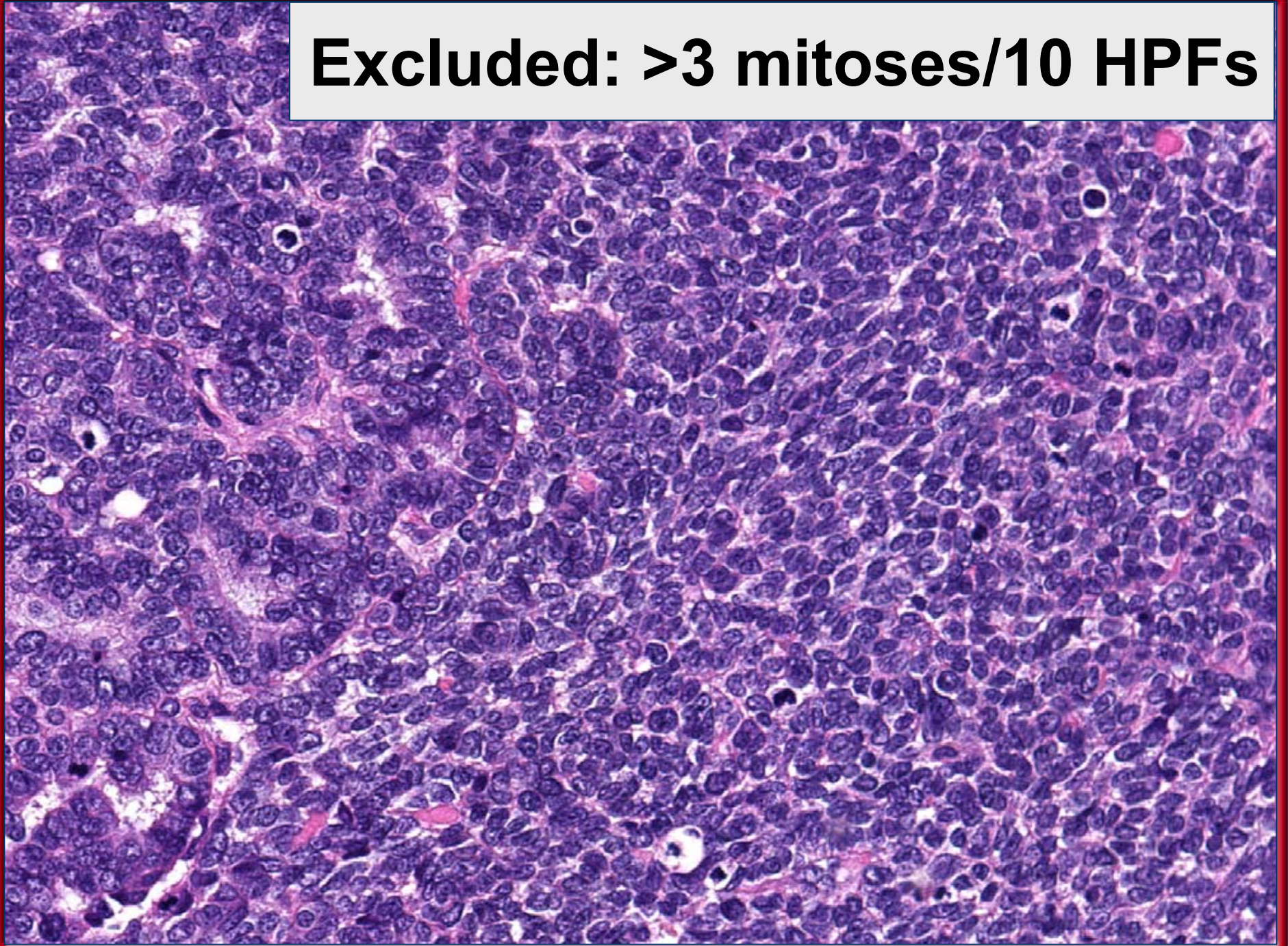


## Excluded: Tumor Necrosis



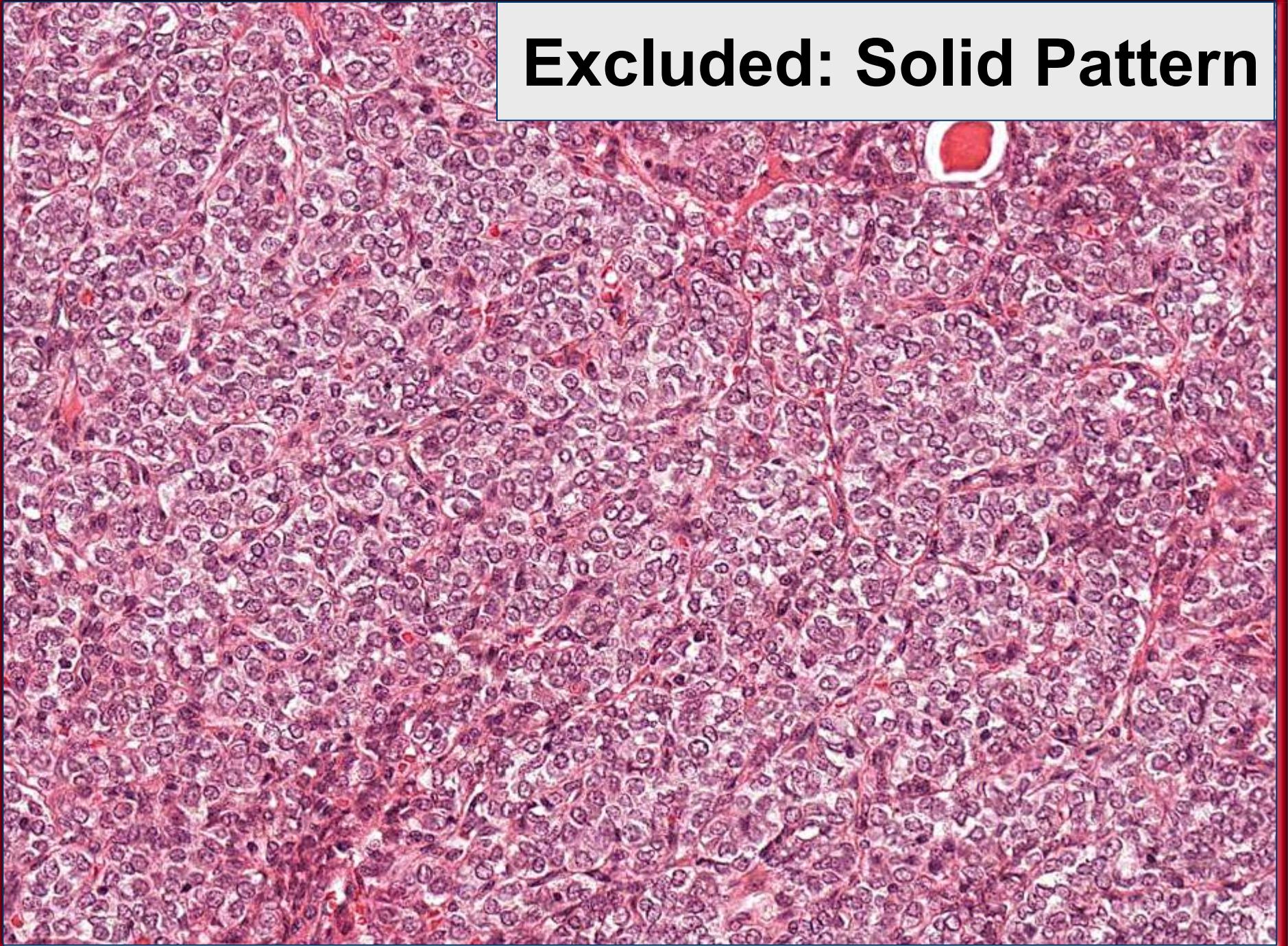


**Excluded:  $>3$  mitoses/10 HPFs**



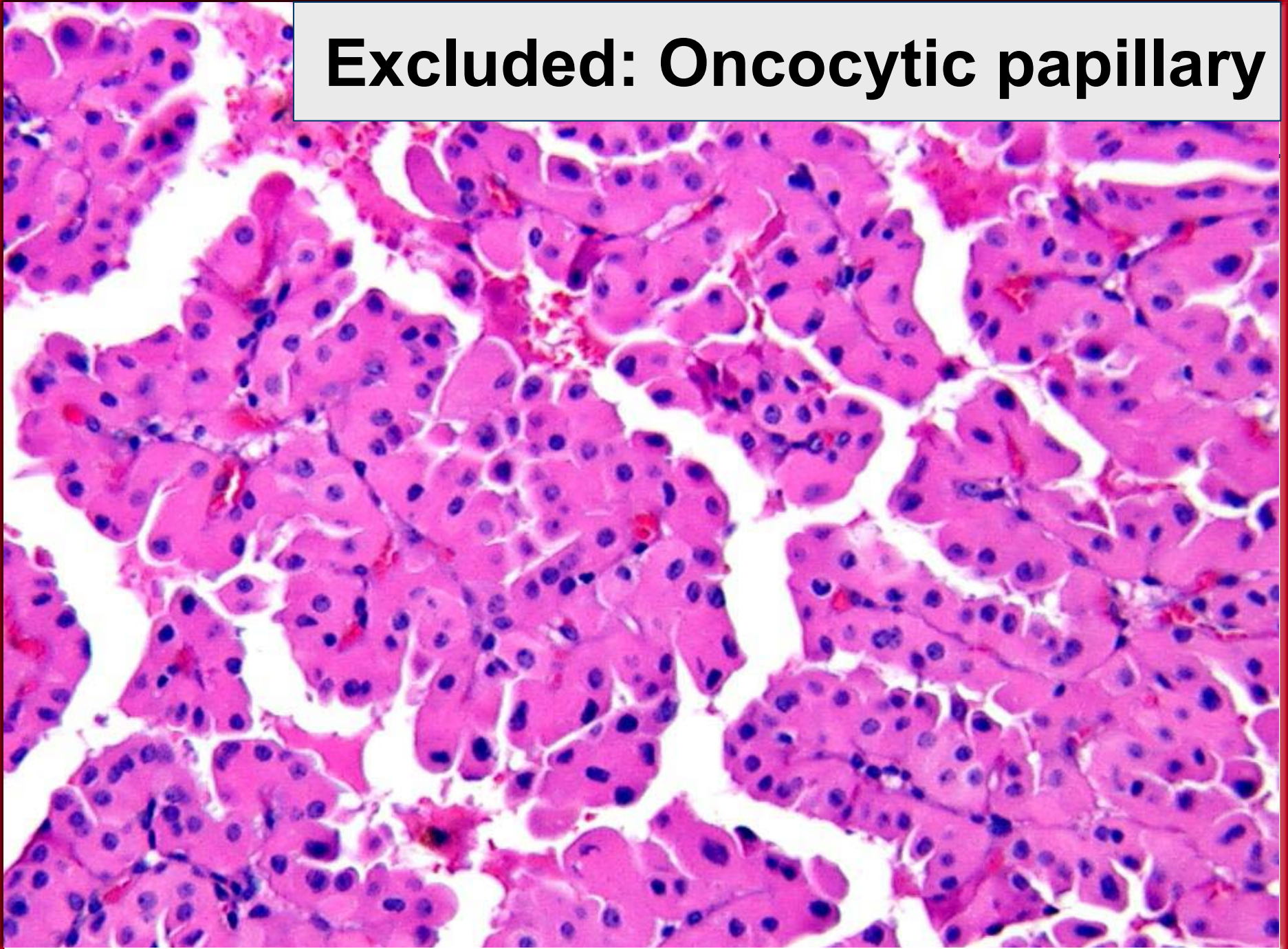


## Excluded: Solid Pattern



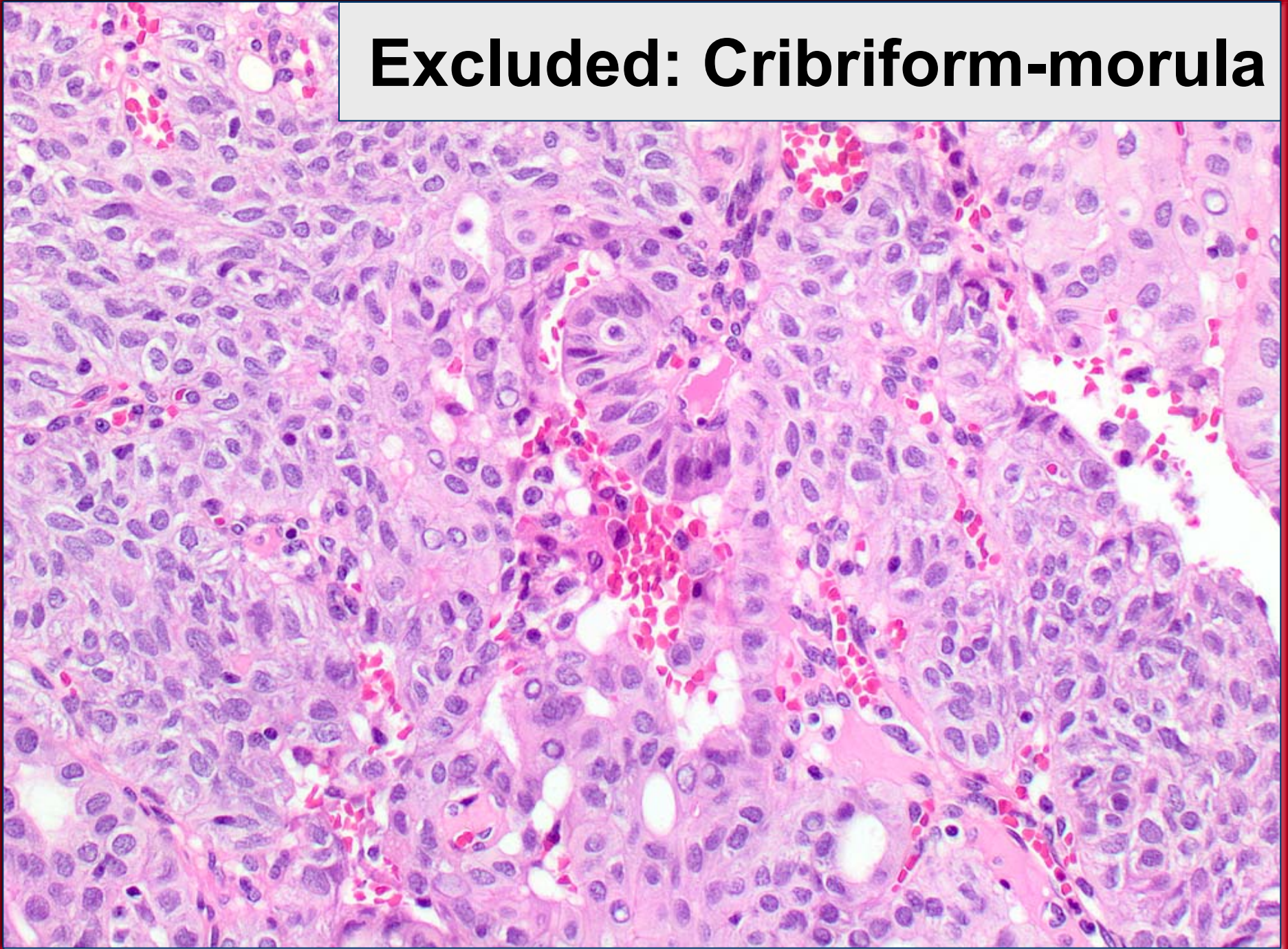


**Excluded: Oncocytic papillary**



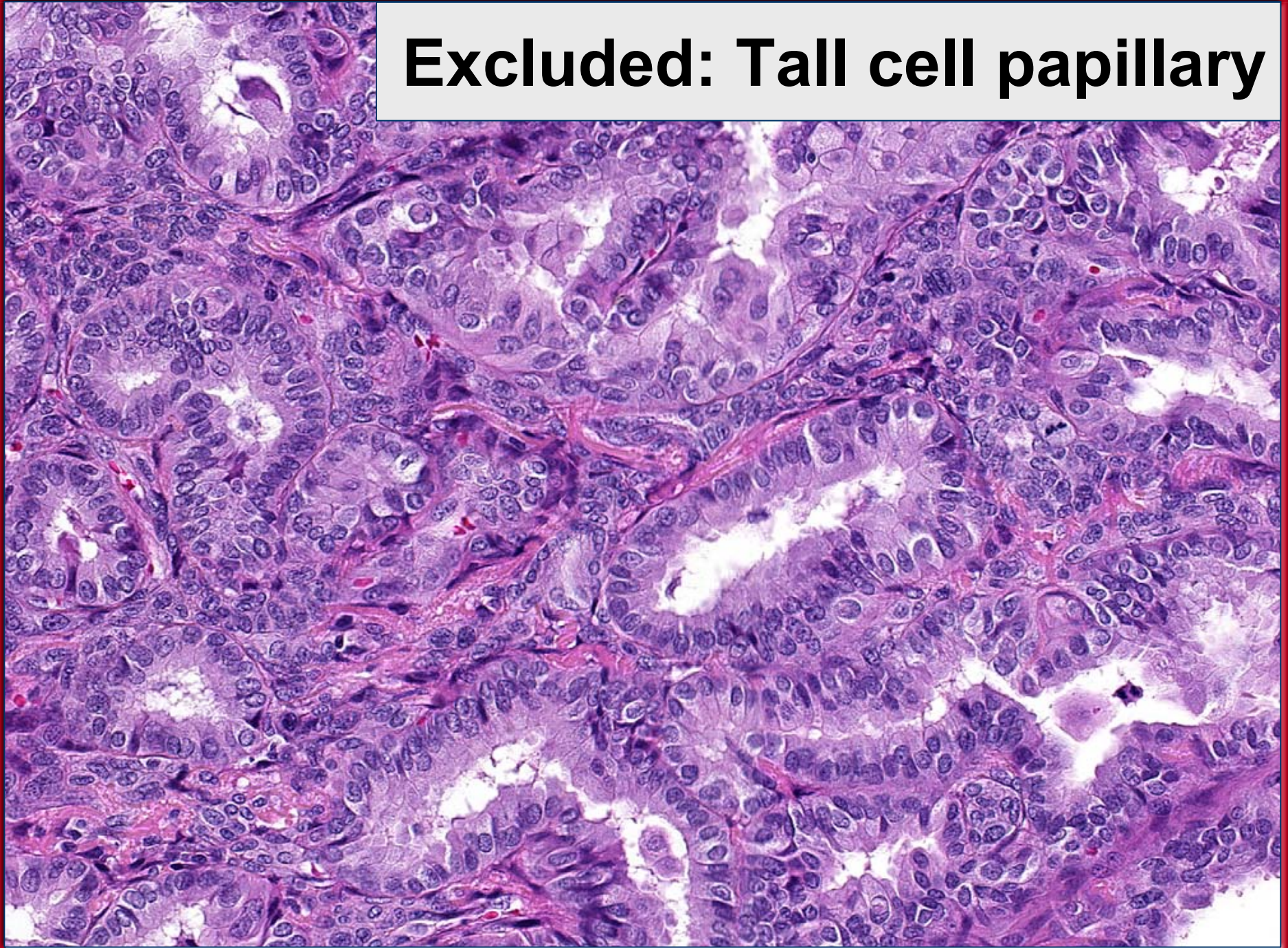


## Excluded: Cribriform-morula



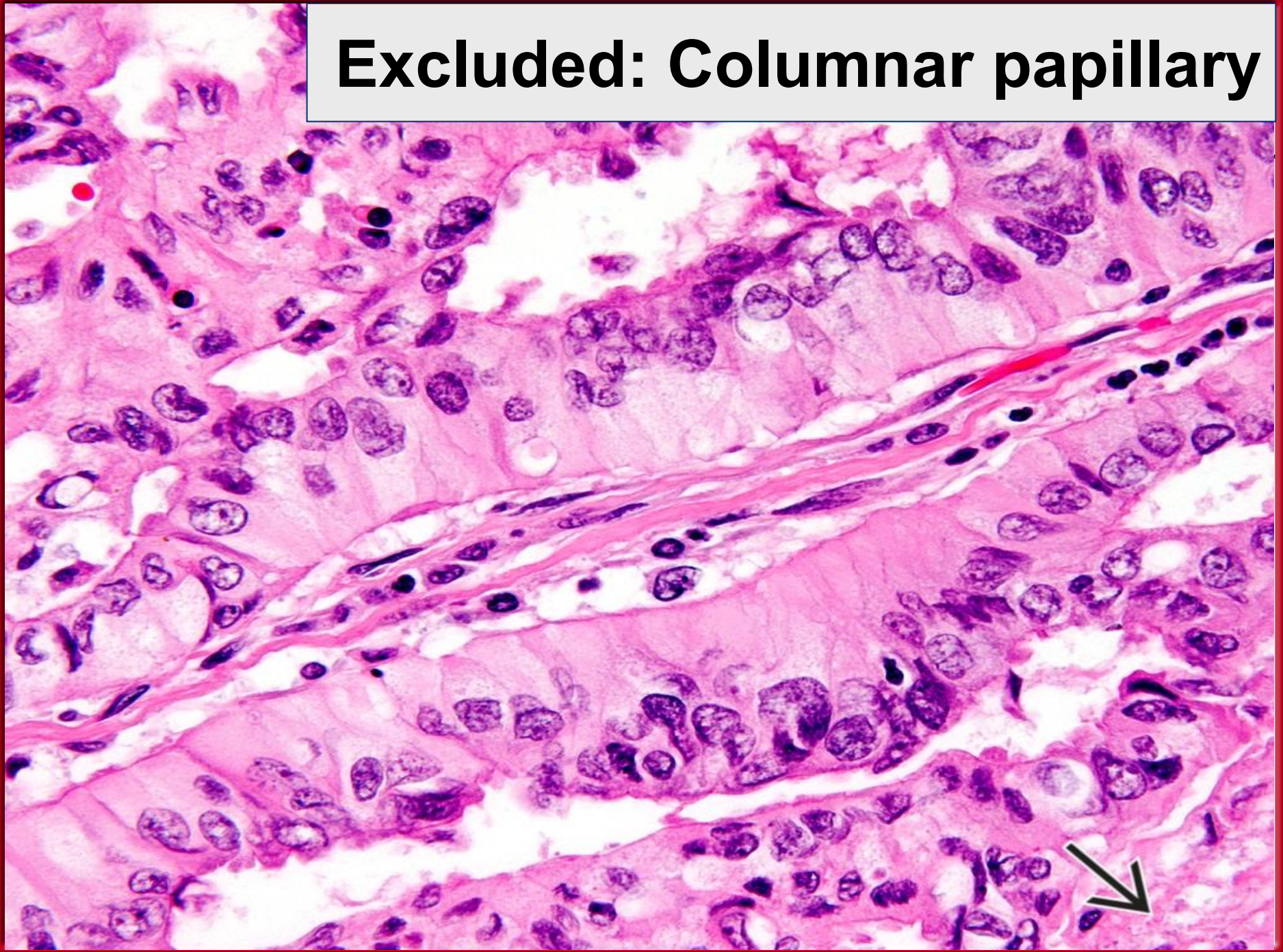


**Excluded: Tall cell papillary**





**Excluded: Columnar papillary**





# Thyroid Papillary Carcinoma: Encapsulated Follicular variant

- **Must have nuclear features of papillary carcinoma**
  - ◆ 1 point each = 3; 2 or more is diagnostic
- **Size and shape (1 point)**
  - ◆ Nuclear enlargement, overlapping, crowding, elongation
- **Nuclear membrane irregularities (1 point)**
  - ◆ Irregular contours, grooves, pseudoinclusions
- **Chromatin characteristics (1 point)**
  - ◆ Clearing with margination, glassy nuclei



# Noninvasive Follicular Thyroid Neoplasm with Papillary-like Nuclei

## Diagnosis rests on cytology

- **Size and shape**
  - ◆ Enlargement, elongation, overlapping/crowding
- **Membrane irregularities**
  - ◆ Irregular contours, grooves/folds, intranuclear cytoplasmic inclusions
- **Chromatin distribution**
  - ◆ Chromatin clearing, margination to membrane, “glassy” nuclei



## **Nuclear score: Sum of three nuclear features (each 0 or 1)**

Thus, total score will vary between 0 and 3

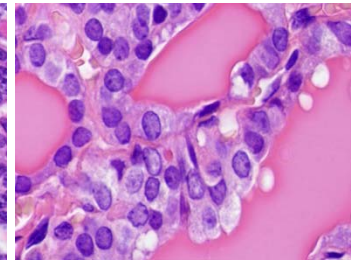
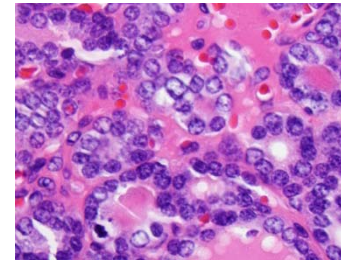
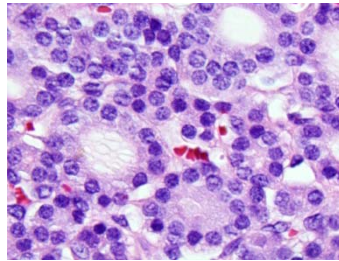
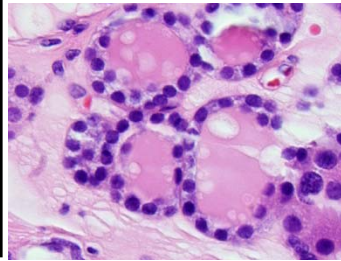
### **Nuclear features:**

### **Absent/insufficiently expressed (0)**

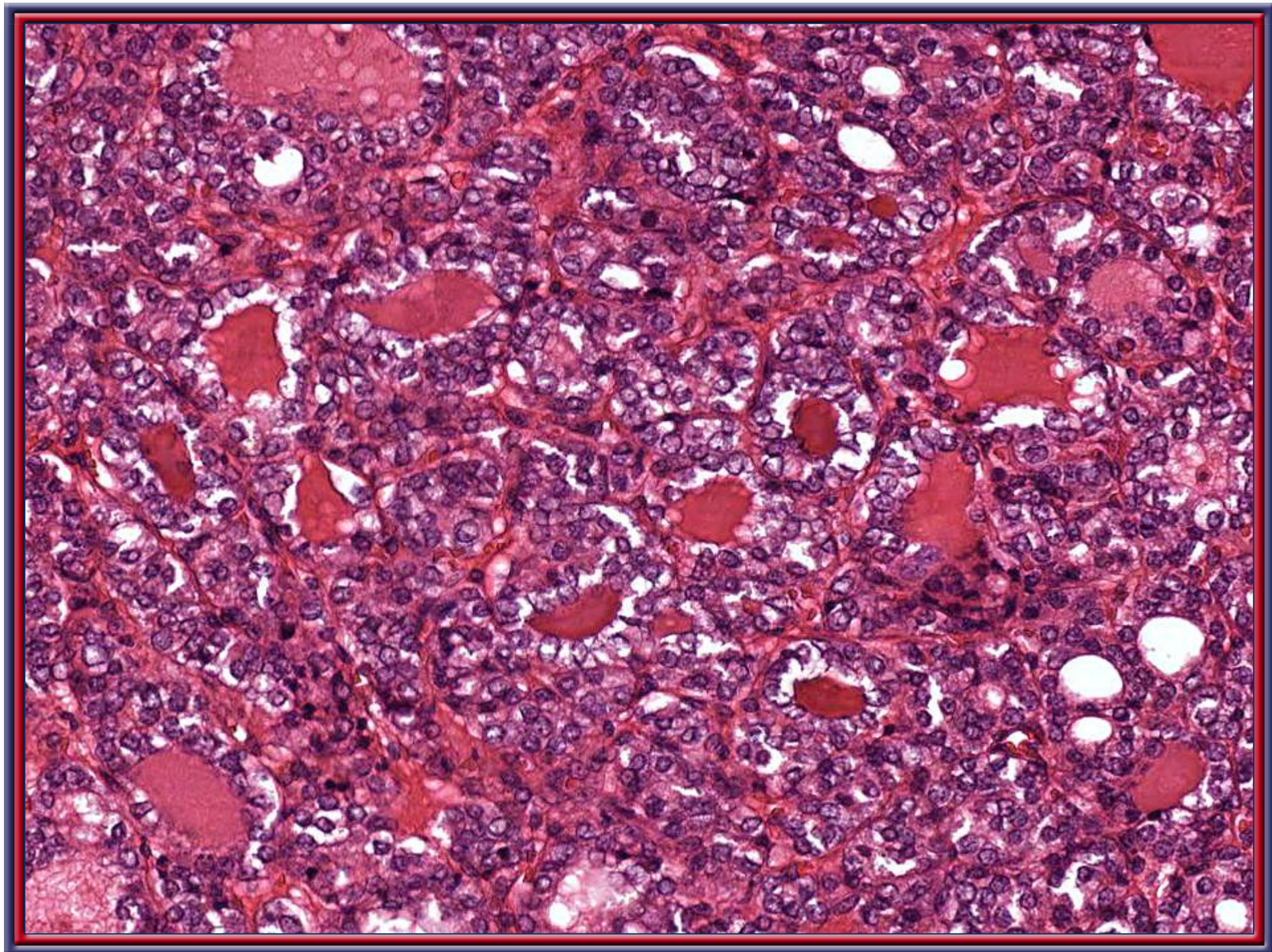
### **Present/Sufficient (1)**

#### **1) Size and Shape**

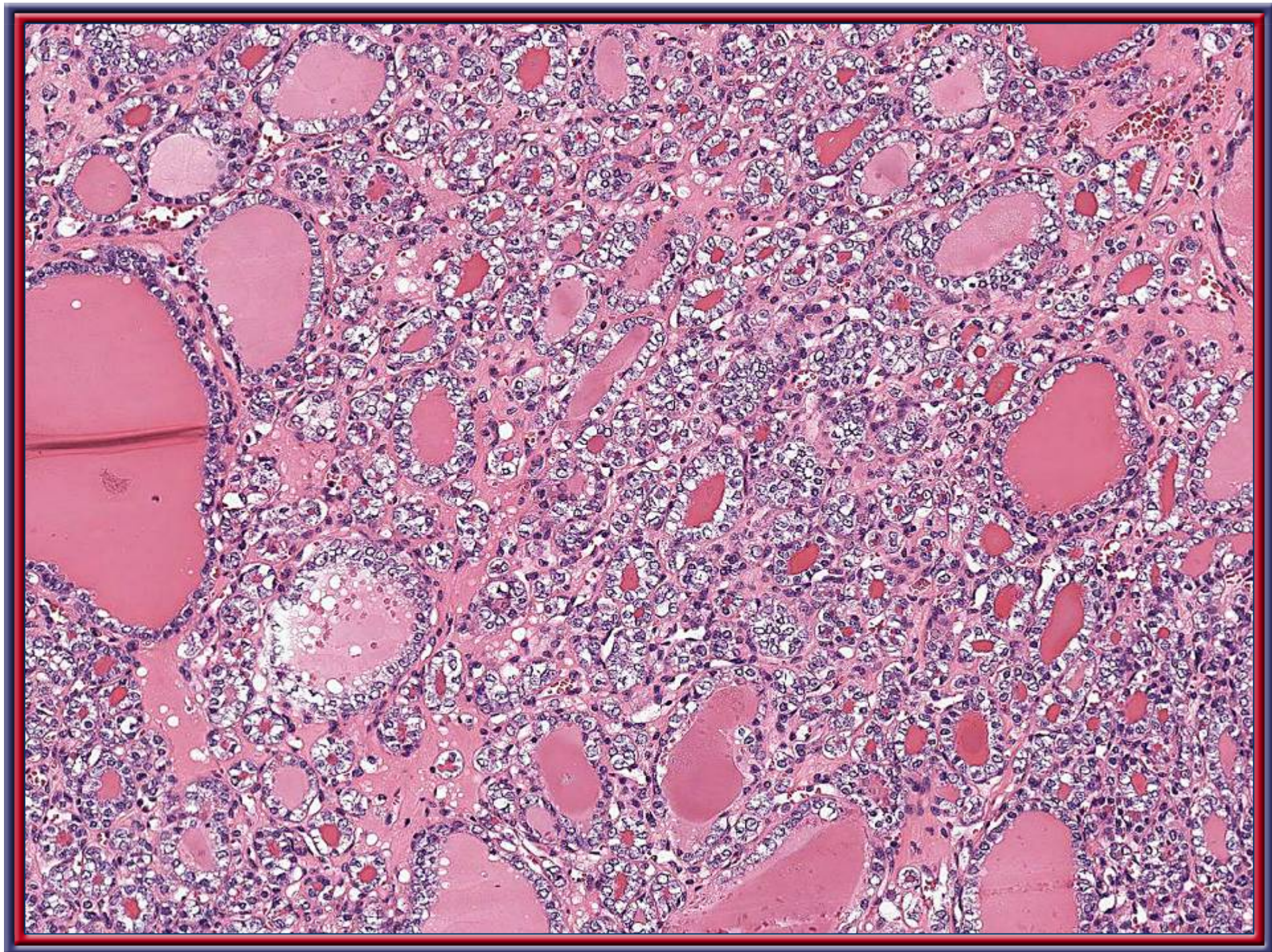
- Enlargement
- Elongation
- Overlapping



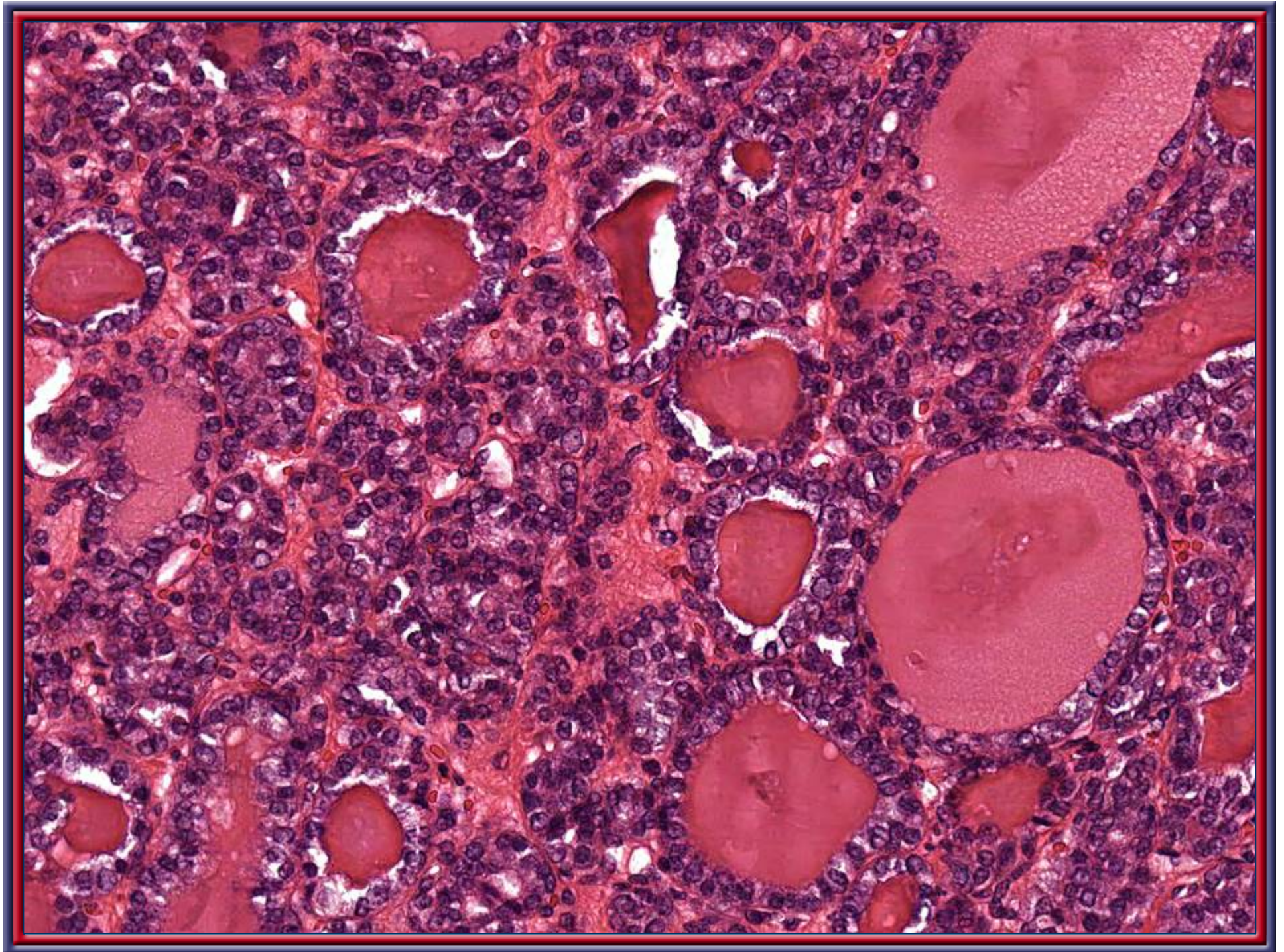














## **Nuclear score: Sum of three nuclear features (each 0 or 1)**

Thus, total score will vary between 0 and 3

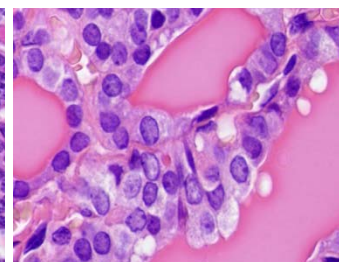
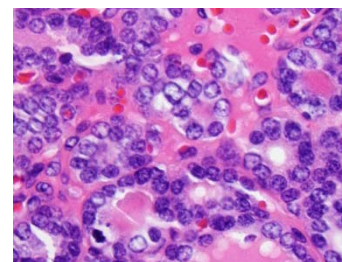
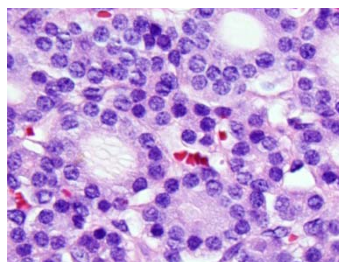
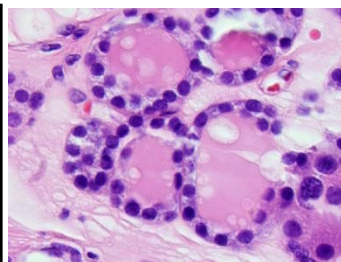
### **Nuclear features:**

### **Absent/insufficiently expressed (0)**

### **Present/Sufficient (1)**

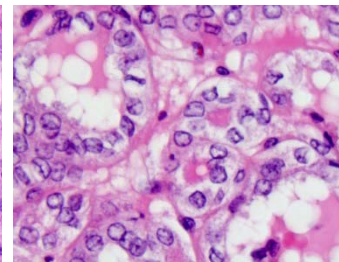
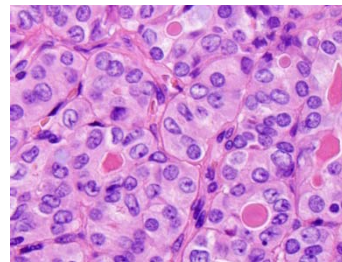
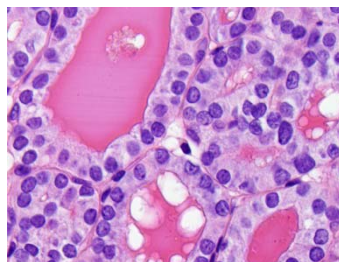
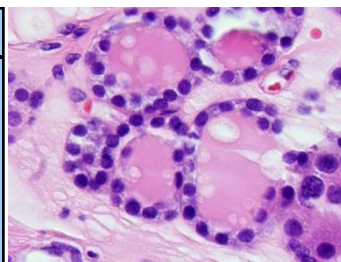
#### **1) Size and Shape**

- Enlargement
- Elongation
- Overlapping

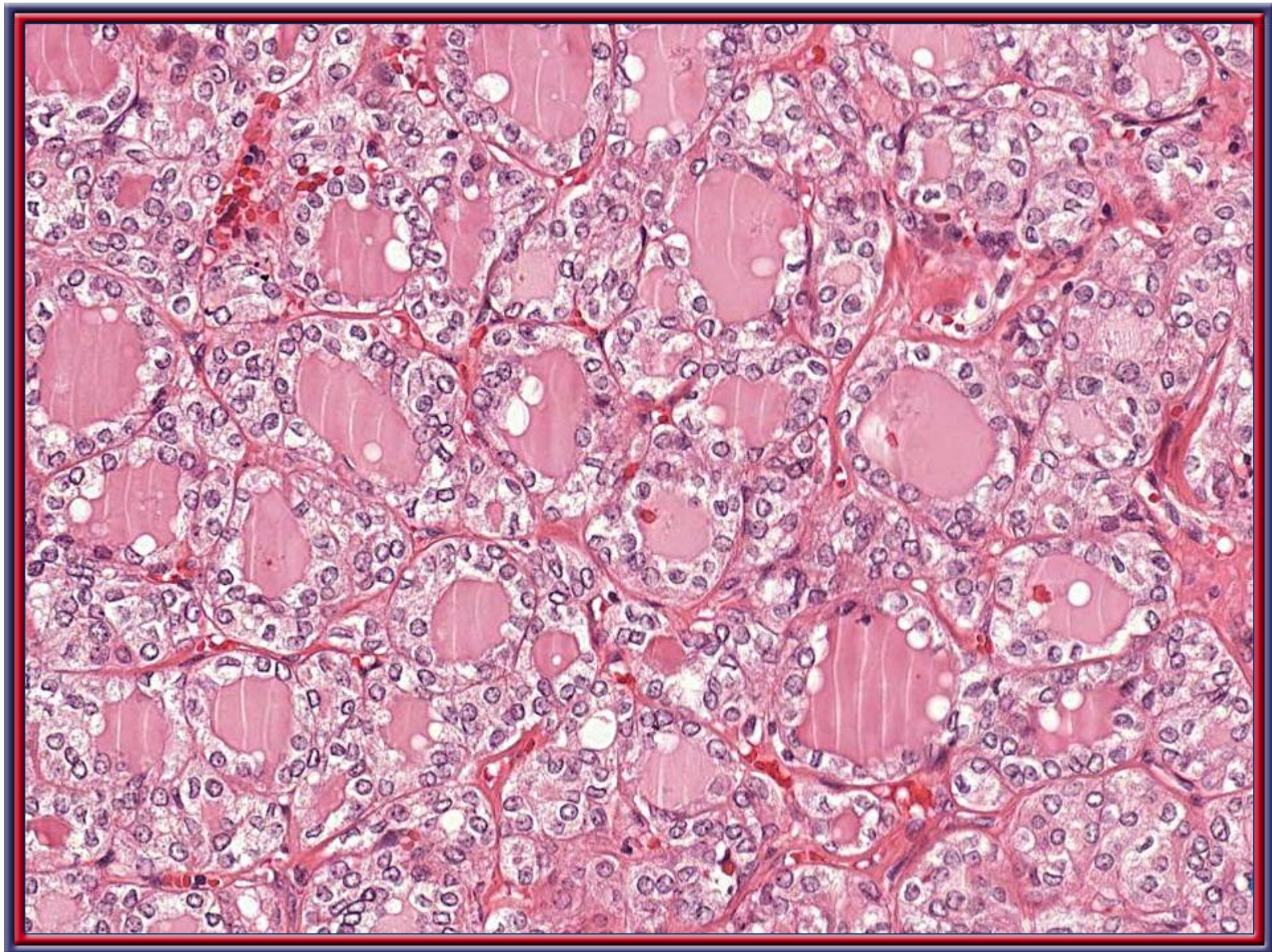


#### **2) Membrane Irregularities**

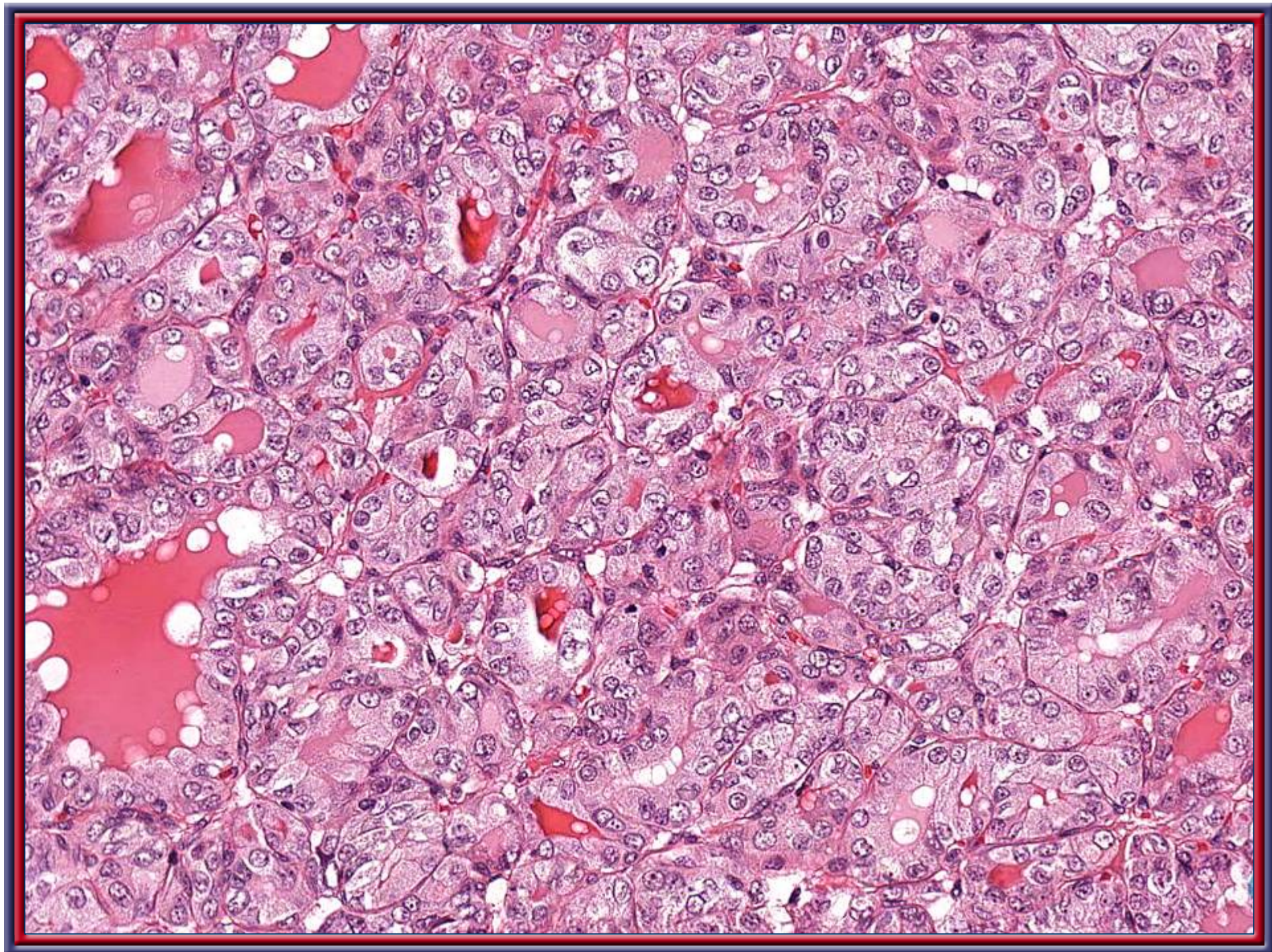
- Irregular contours
- Grooves
- Intranuclear cytoplasmic inclusions



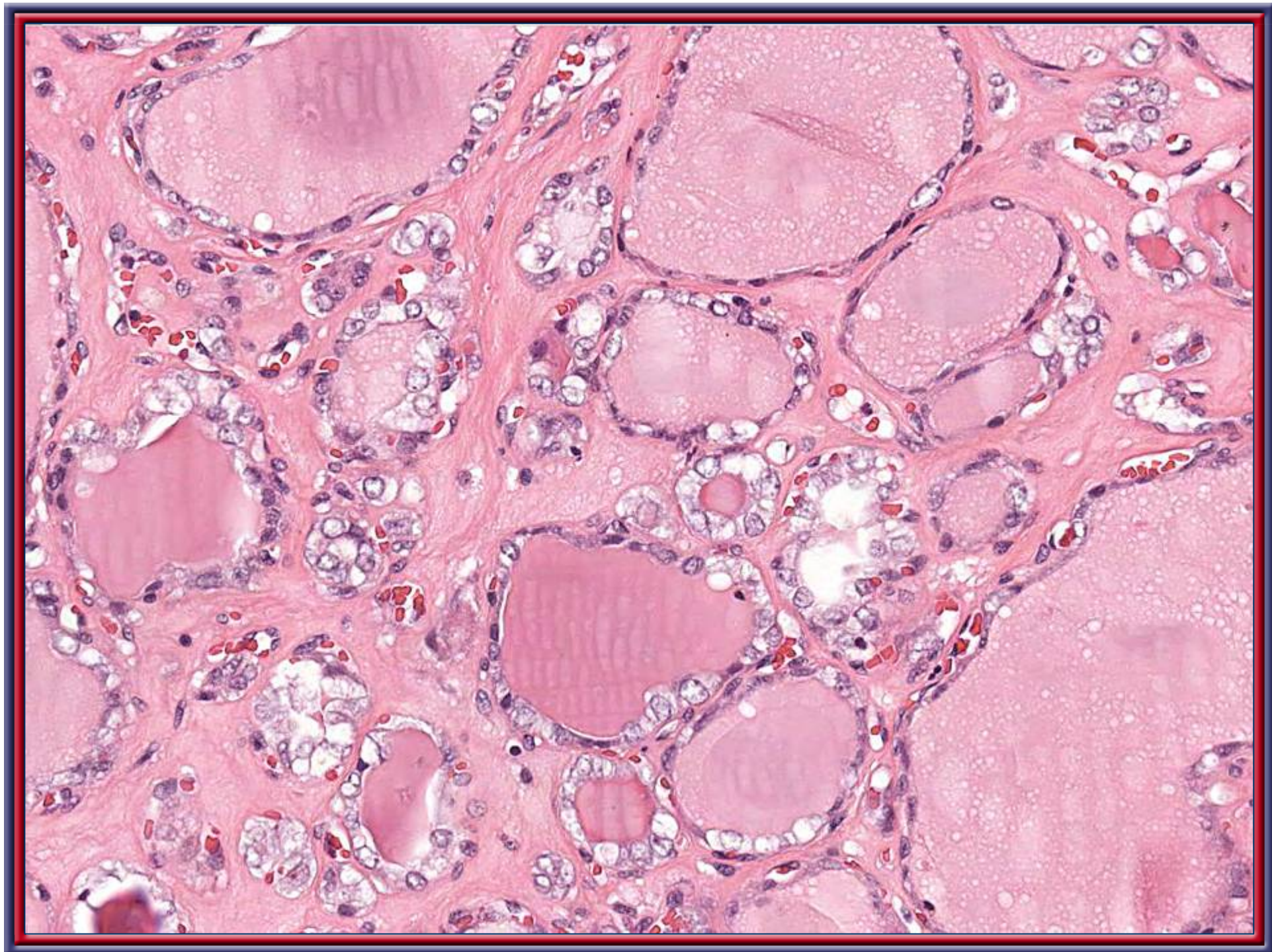














## **Nuclear score: Sum of three nuclear features (each 0 or 1)**

Thus, total score will vary between 0 and 3

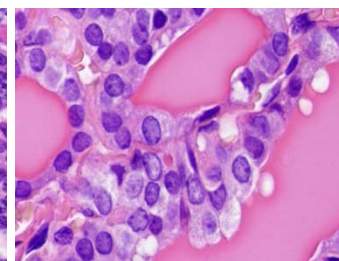
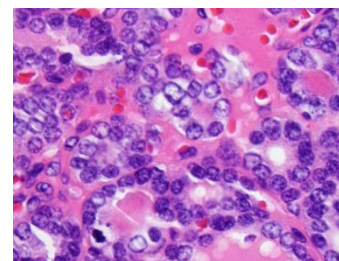
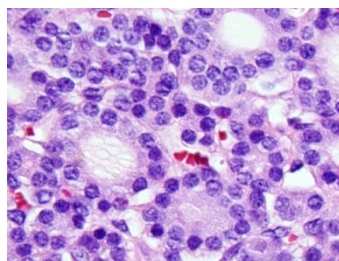
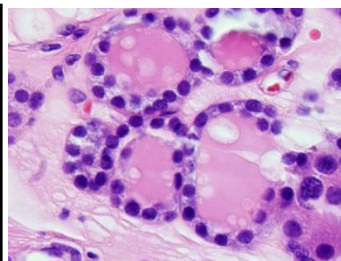
### **Nuclear features:**

### **Absent/insufficiently expressed (0)**

### **Present/Sufficient (1)**

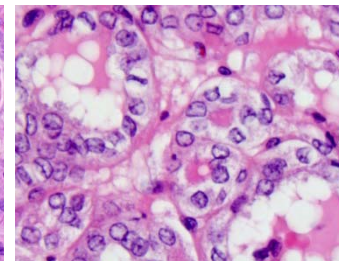
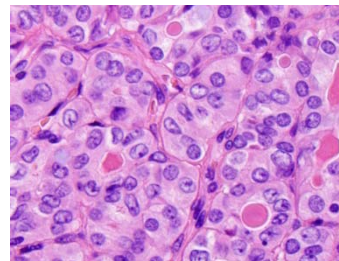
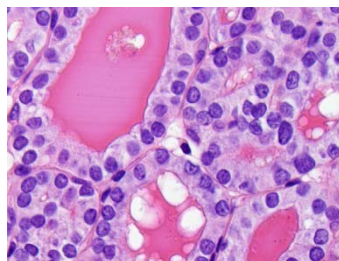
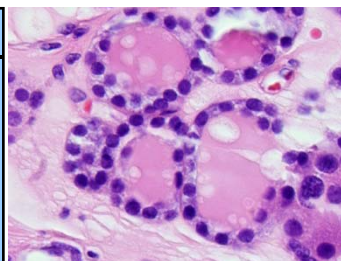
#### **1) Size and Shape**

- Enlargement
- Elongation
- Overlapping



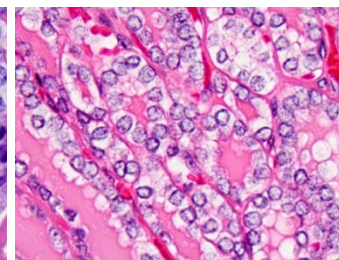
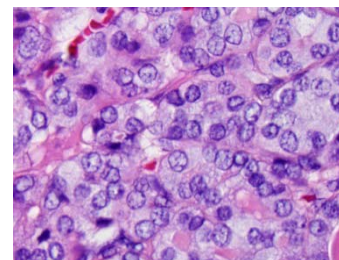
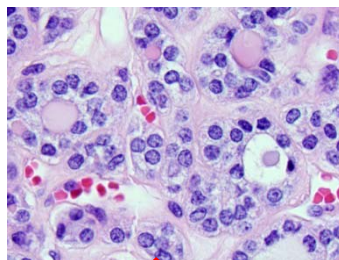
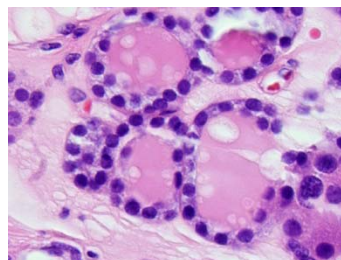
#### **2) Membrane Irregularities**

- Irregular contours
- Grooves
- Intranuclear cytoplasmic inclusions



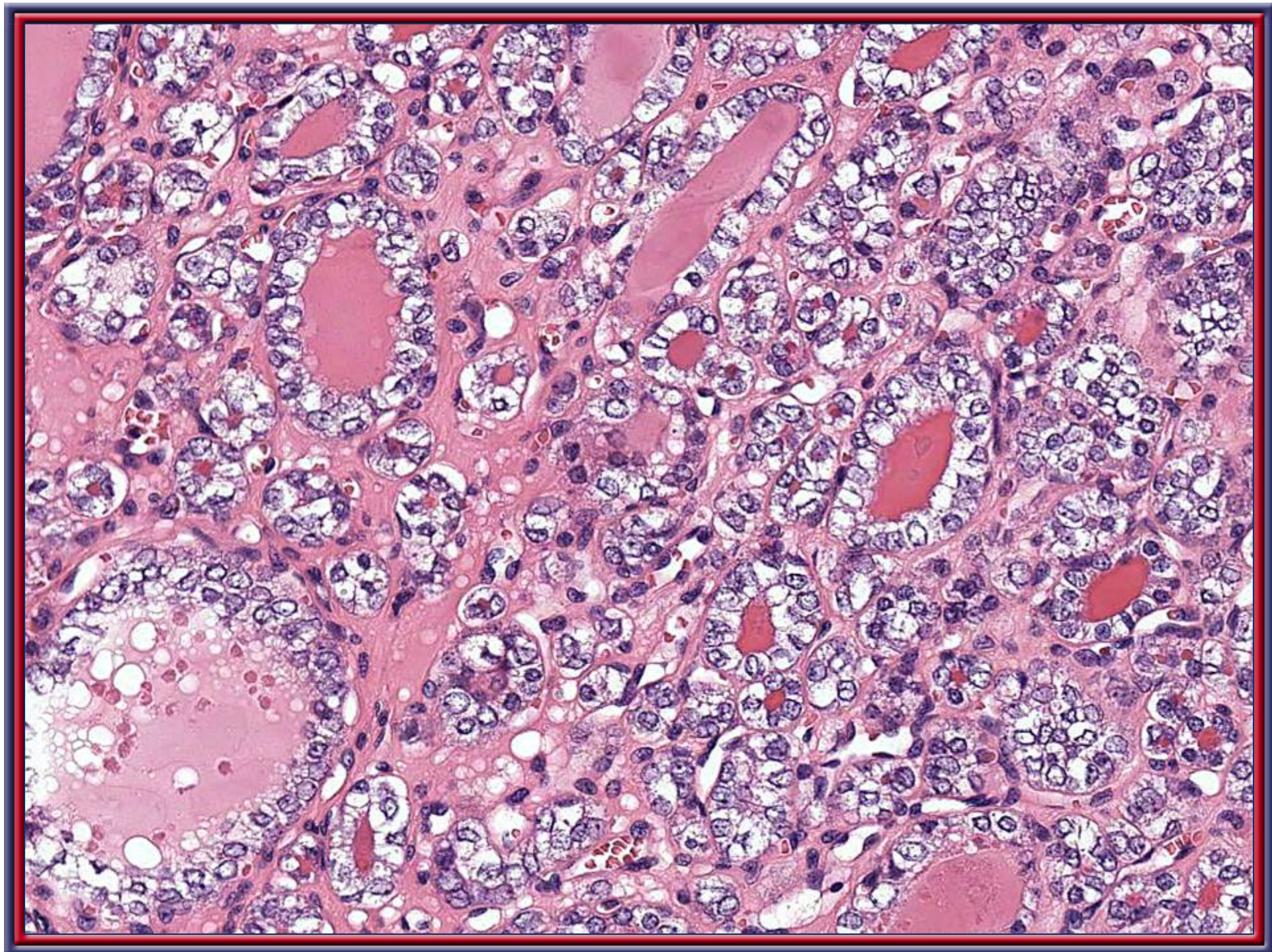
#### **3) Chromatin Features**

- Chromatin clearing
- Margination to nuclear membrane
- Glassy nuclei

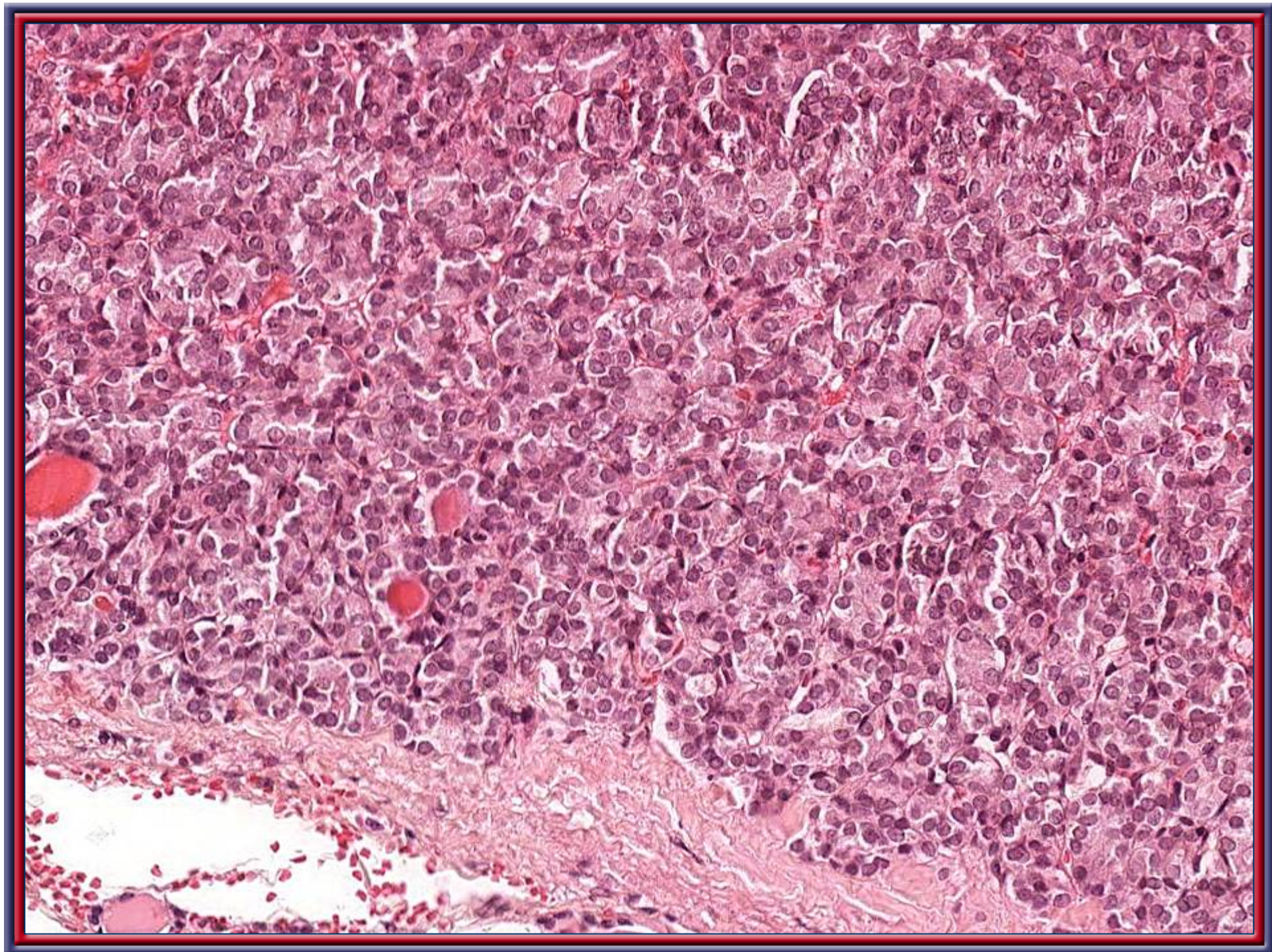


**Slight changes not sufficient to call "present"!**

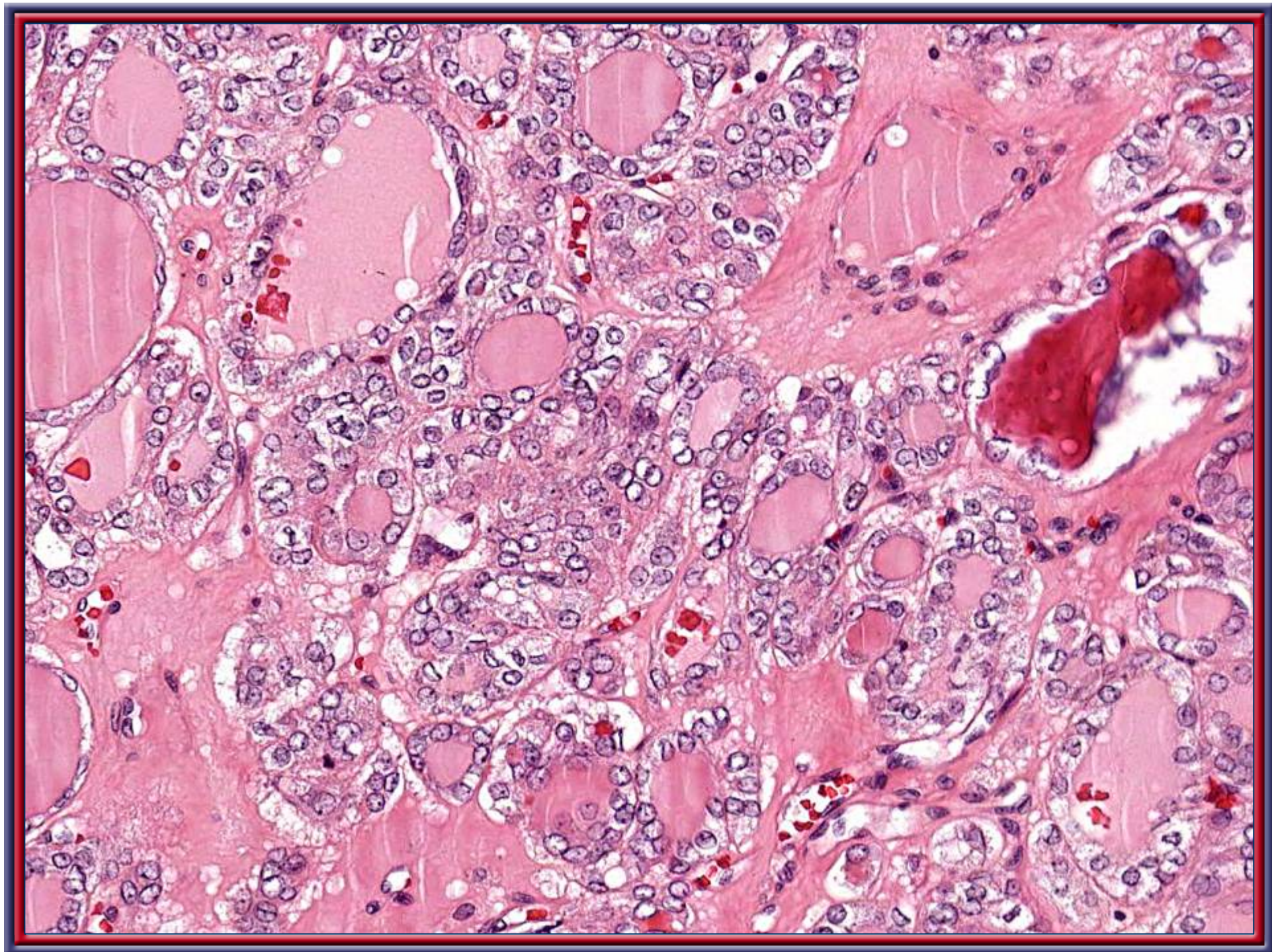










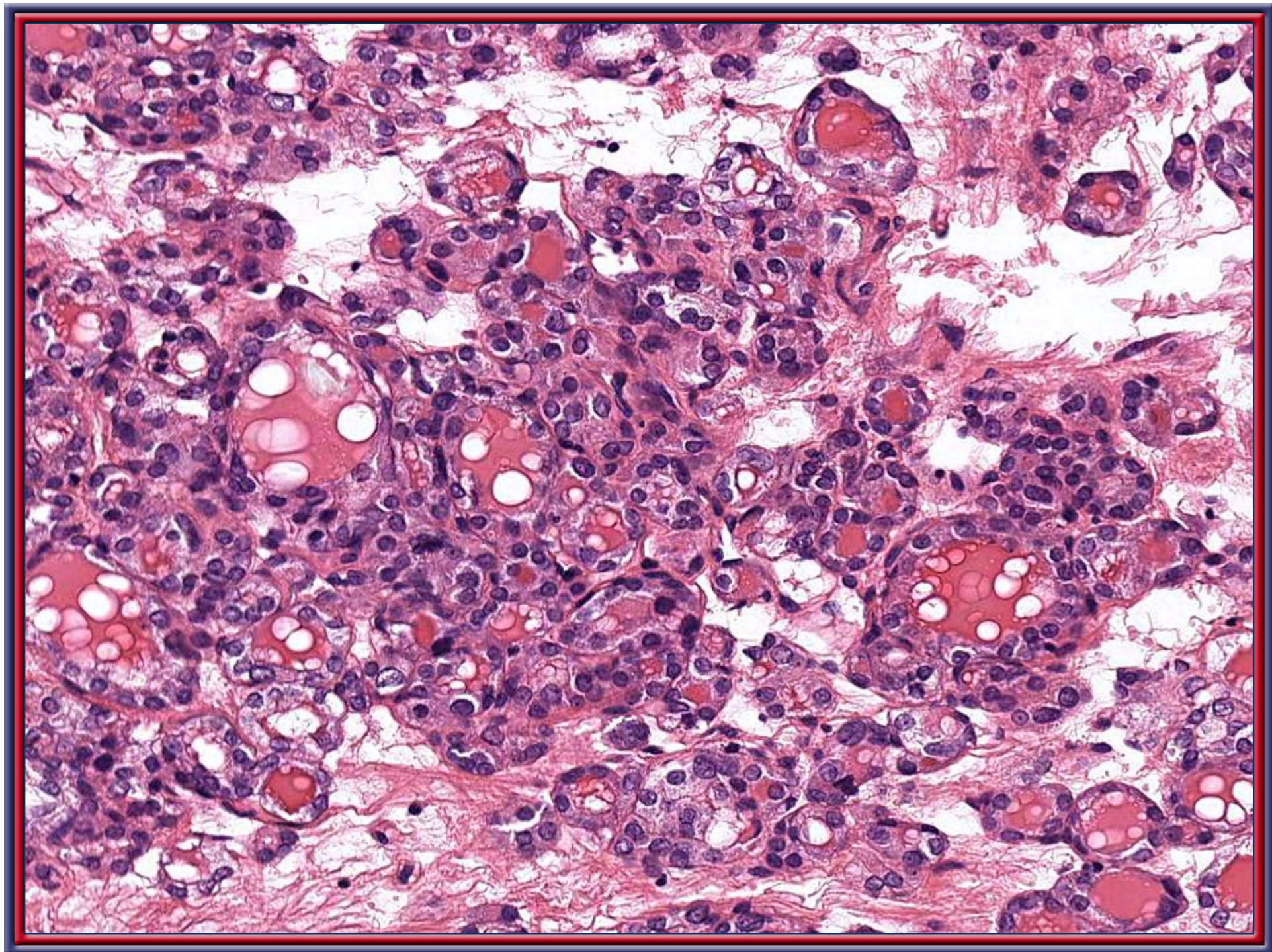




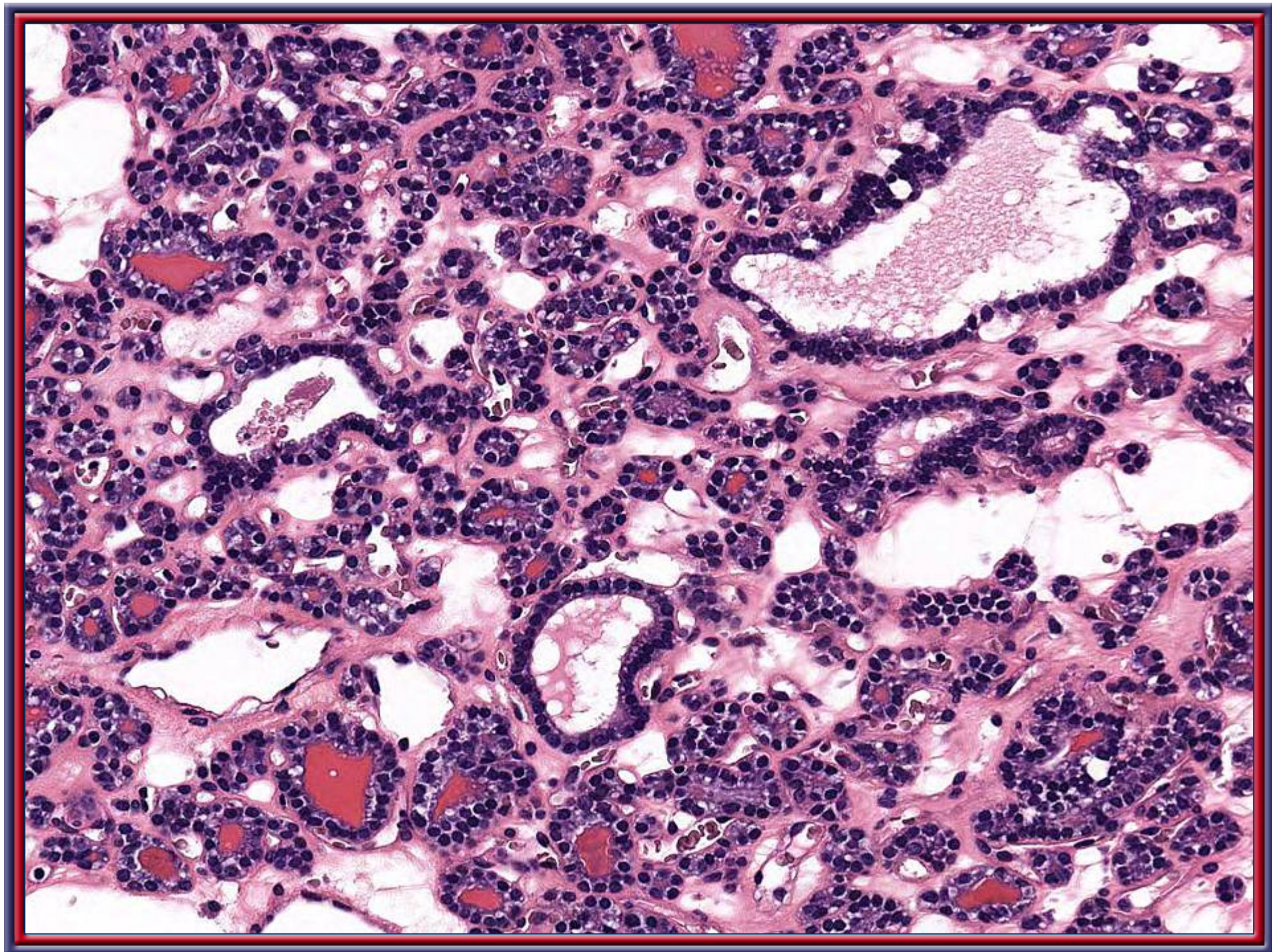
## Non-invasive Follicular Thyroid Neoplasm with Papillary-like Nuclei

- **How much of the tumor must have nuclear feature?**
  - ◆ 3 foci per cm of tumor gross measurement
  - ◆ This is not well defined or agreed upon
  - ◆ May be multifocal within same nodule

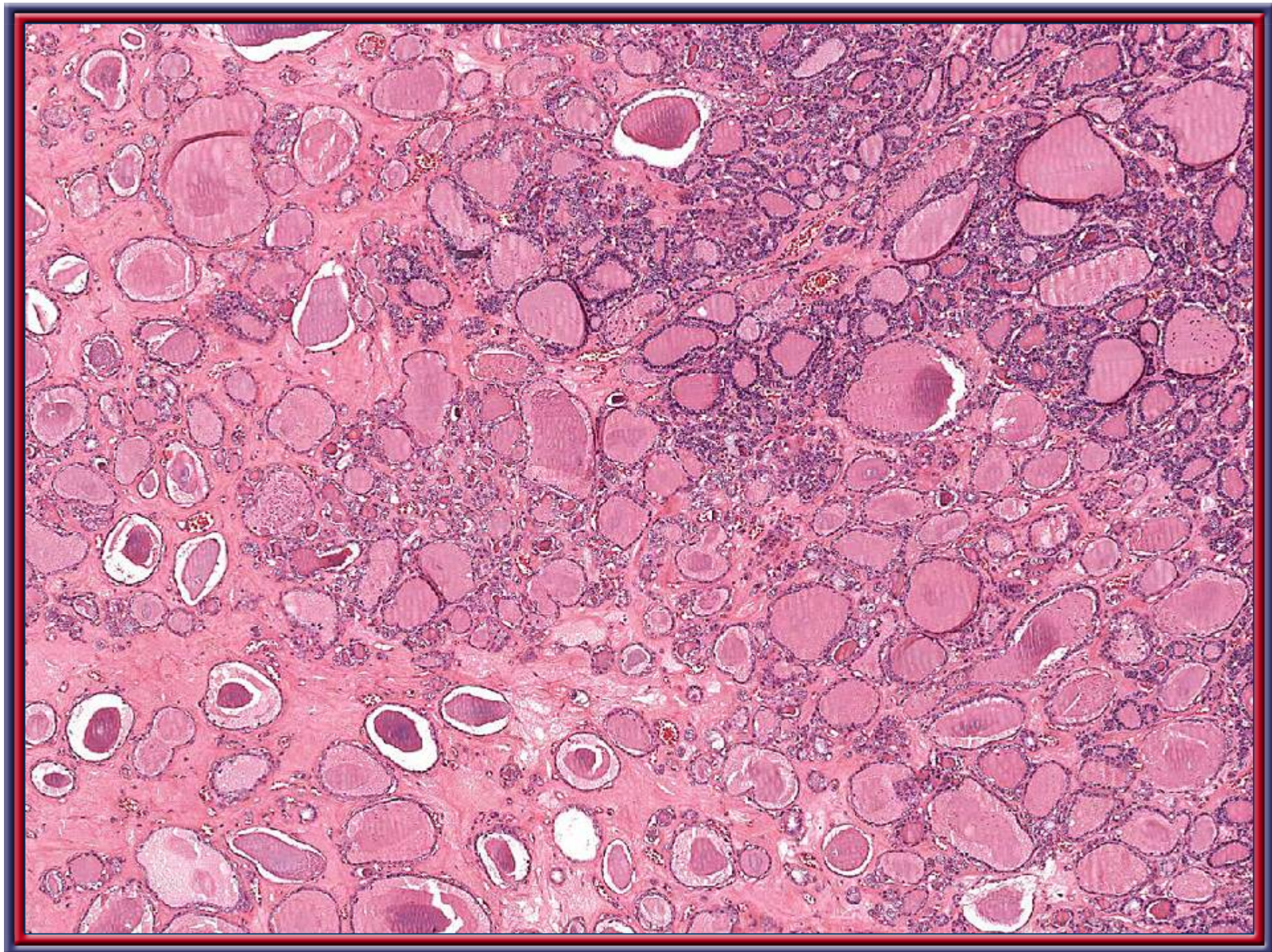




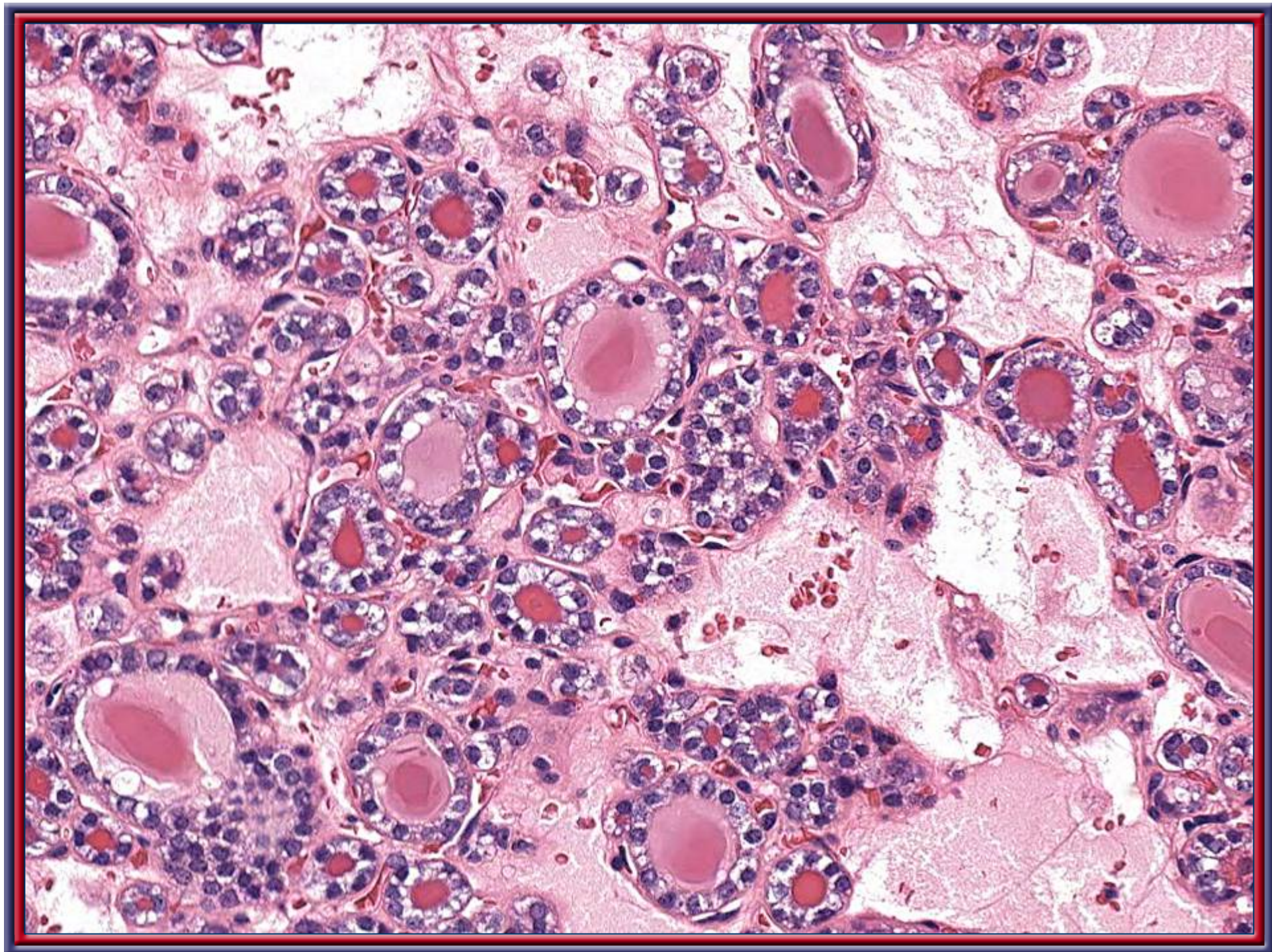




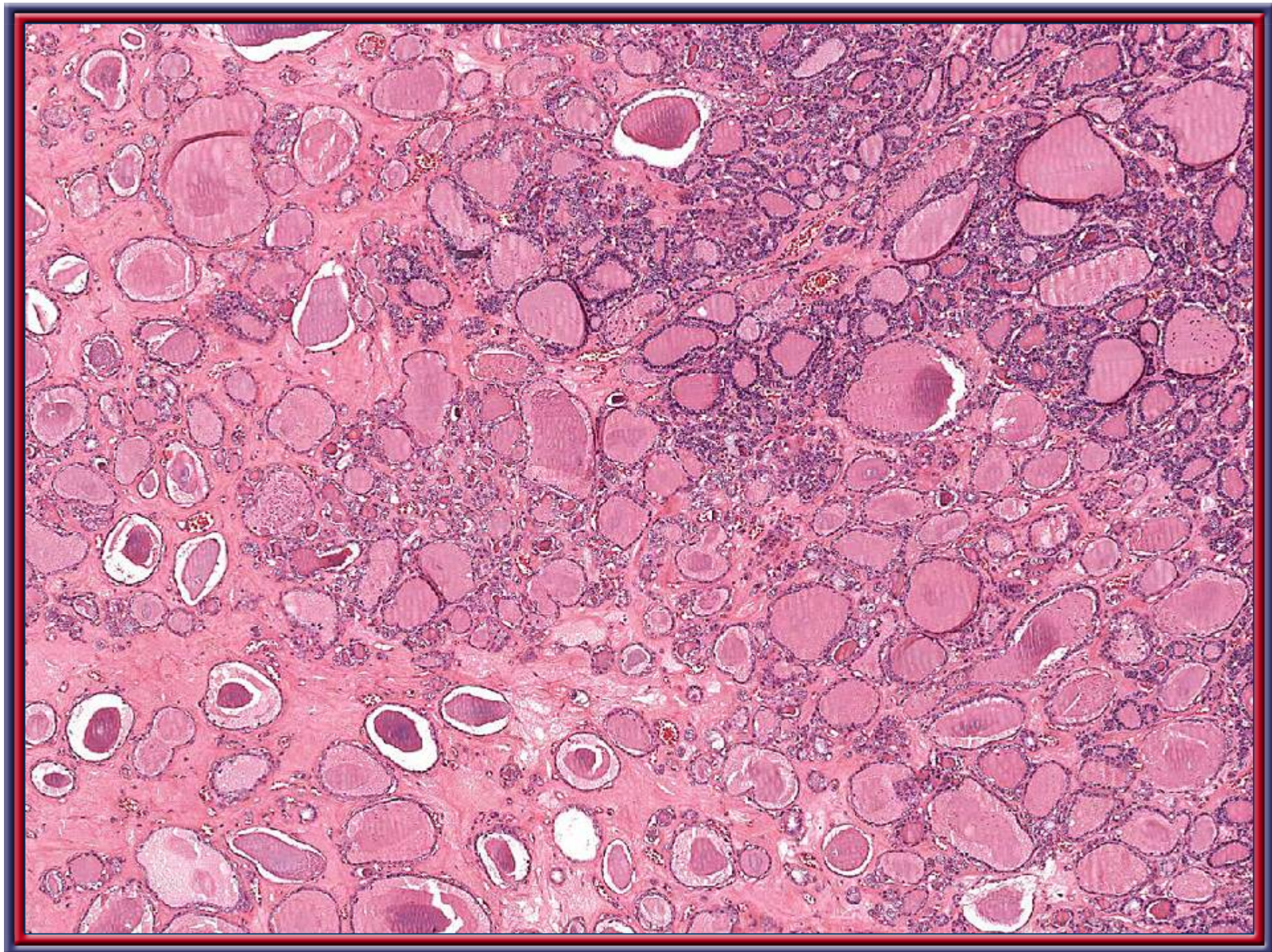




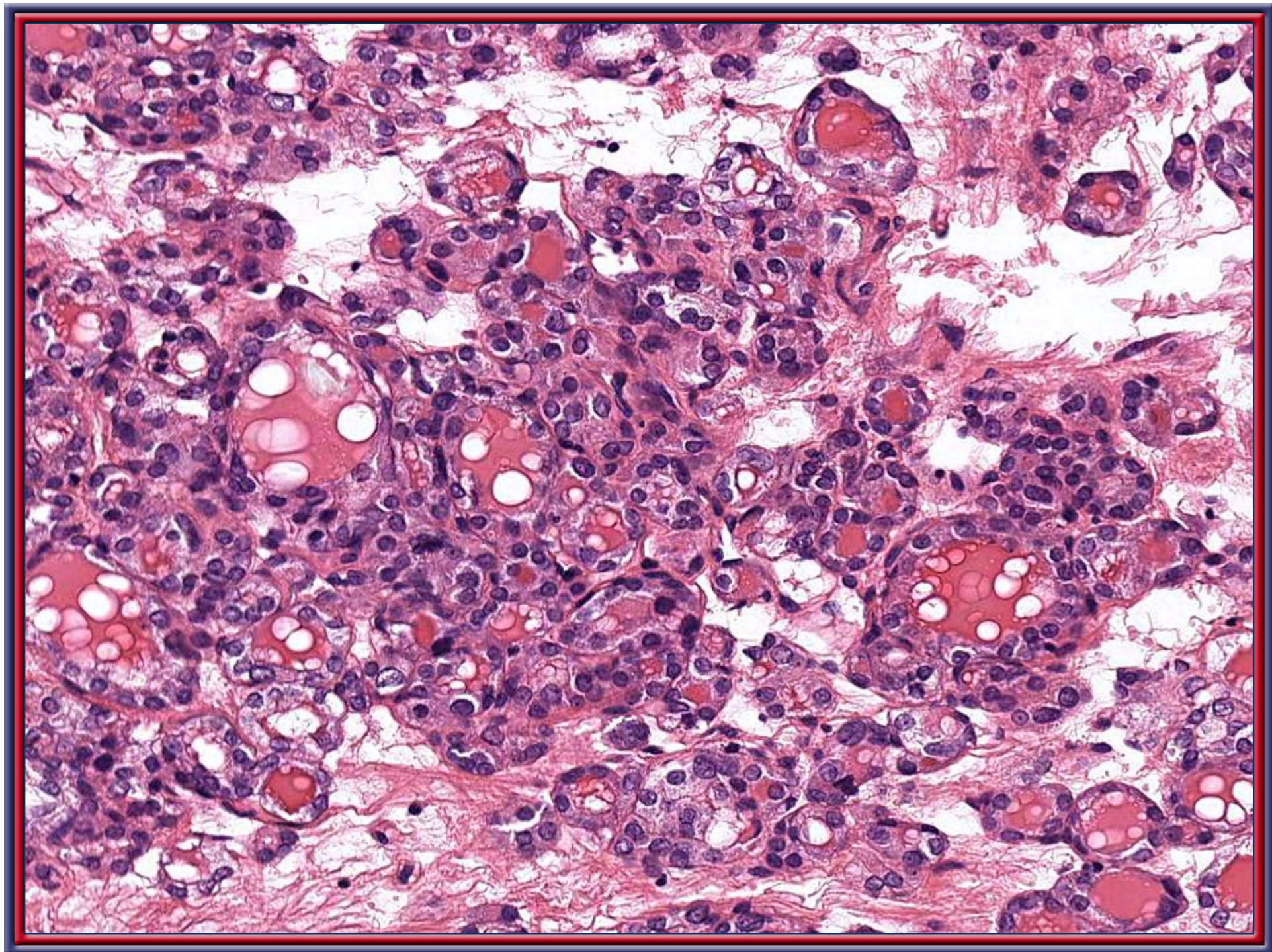




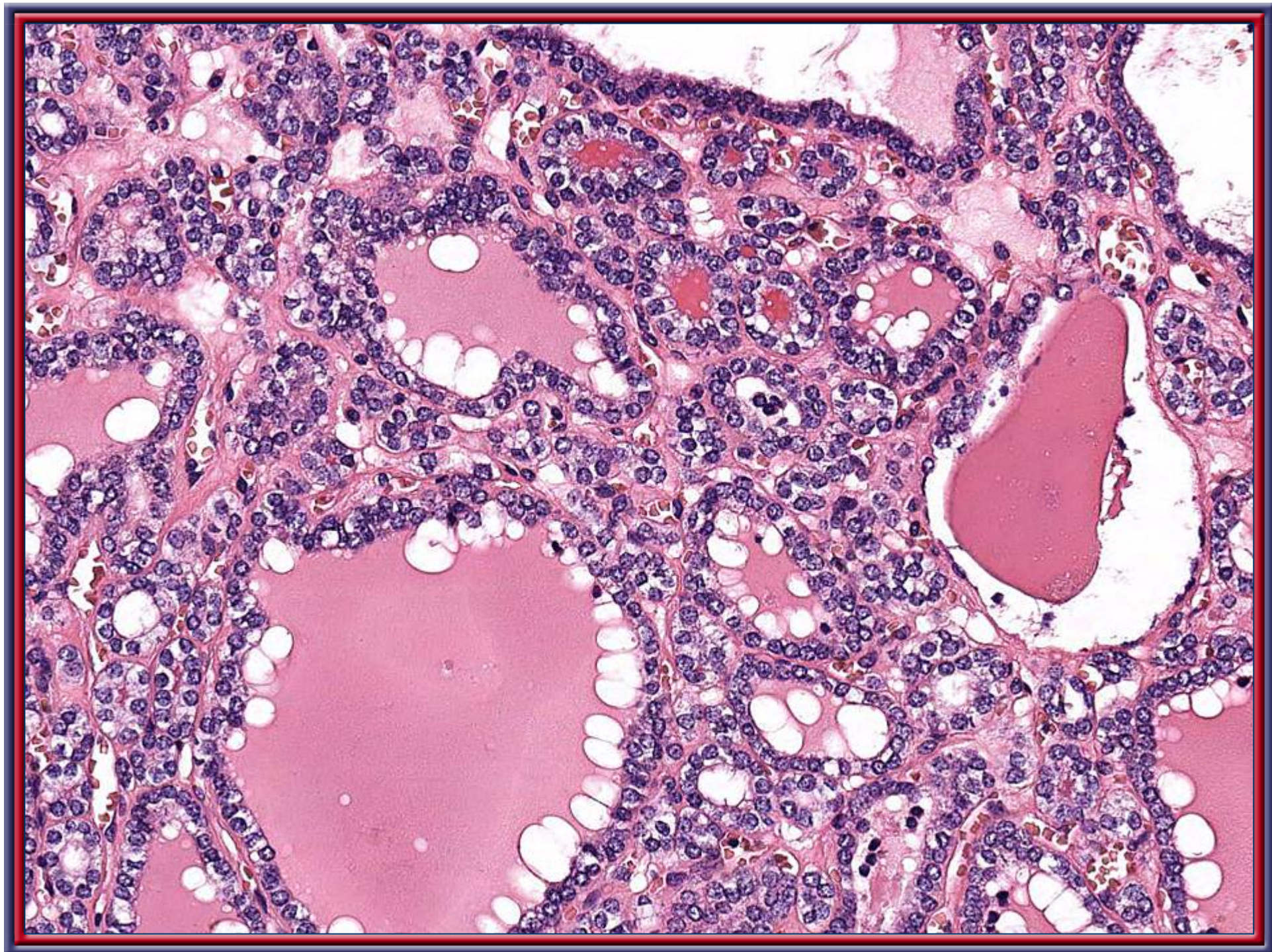




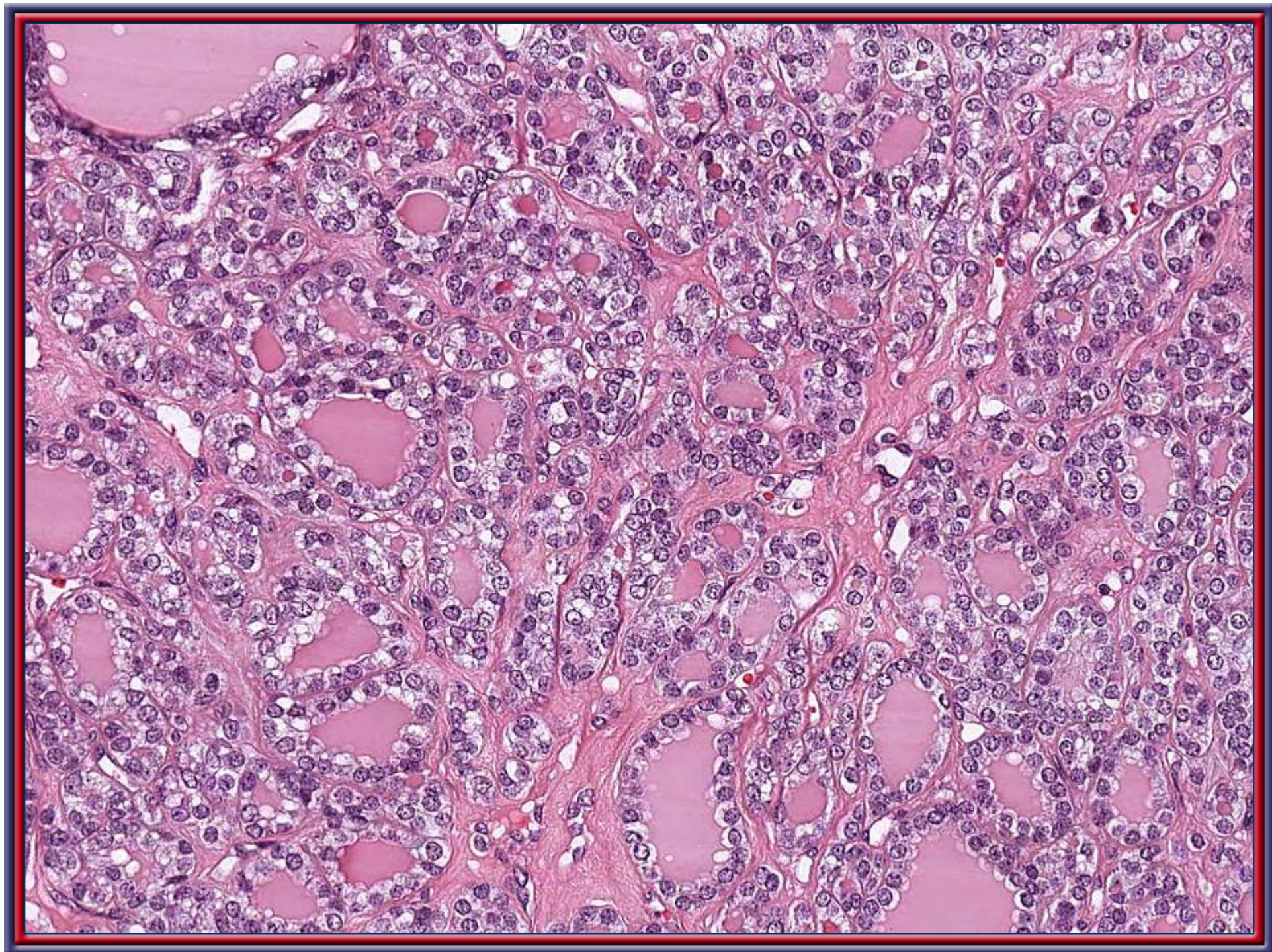














# ***NIFTP***

## ***Noninvasive Follicular Thyroid Neoplasm with Papillary-like Nuclear Features***